

Recommendations for the practice of echocardiography in infective endocarditis

Gilbert Habib (France)*, Luigi Badano (Italy), Christophe Tribouilloy (France), Isidre Vilacosta (Spain), and Jose Luis Zamorano (Spain)

Scientific Committee: Maurizio Galderisi (Italy), Jens-Uwe Voigt (Belgium), Rosa Sicari (Italy)

Document Reviewers: Bernard Cosyns (Belgium), Kevin Fox (UK), Svend Aakhus (Norway)

On behalf of the European Association of Echocardiography

Service de Cardiologie, CHU La Timone, Bd Jean Moulin, 13005 Marseille, France

Received 20 December 2009; accepted after revision 30 December 2009

Echocardiography plays a key role in the assessment of infective endocarditis (IE). It is useful for the diagnosis of endocarditis, the assessment of the severity of the disease, the prediction of short- and long-term prognosis, the prediction of embolic events, and the follow-up of patients under specific antibiotic therapy. Echocardiography is also useful for the diagnosis and management of the complications of IE, helping the physician in decision-making, particularly when a surgical therapy is considered. Finally, intraoperative echocardiography must be performed in IE to help the surgeon in the assessment and management of patients with IE during surgery. The current 'recommendations for the practice of echocardiography in infective endocarditis' aims to provide both an updated summary concerning the value and limitations of echocardiography in IE, and clear and simple recommendations for the optimal use of both transthoracic and transoesophageal echocardiography in IE.

Keywords Echocardiography • Endocarditis • Valve disease

Table of Contents

Introduction	202	2. Echocardiographic follow-up under therapy	212
Chapter 1: Echocardiography for the diagnosis of infective endocarditis	203	3. Follow-up after discharge and long-term prognosis.	212
1. When to perform echocardiography in infective endocarditis?.	203	Chapter 4: Intraoperative echocardiography.	212
2. Transthoracic or transoesophageal echocardiography in suspected infective endocarditis?.	203	Chapter 5: Echocardiography in specific clinical conditions	213
3. Anatomical features	203	1. Prosthetic valve infective endocarditis	213
4. Echocardiographic criteria	204	2. Cardiac device-related infective endocarditis.	214
5. Limitations and pitfalls of echocardiography for the diagnosis of infective endocarditis	205	3. Right heart infective endocarditis	215
Chapter 2: Echocardiography for the diagnosis and management of complications of infective endocarditis.	207	4. Negative blood culture infective endocarditis	217
1. Heart failure/haemodynamic indications	207	Conclusion and future directions.	217
2. Perivalvular extension/infectious indications	208		
3. Embolic events/embolic indications	210		
4. Other complications.	211		
Chapter 3: Echocardiography for the follow-up and prognostic assessment of IE	211		
1. Prognostic assessment at admission.	211		

Introduction

Infective endocarditis (IE) is a life-threatening disease still associated with a high mortality rate.^{1,2} Several complications may occur during the course of IE, including embolic events, perivalvular extension, and valvular destruction causing heart failure. These main complications are the cause of the persistent high morbidity and mortality of the disease.³ They are also the main reasons for

* Corresponding author. Tel: +33 4 91 38 63 79, Email: gilbert.habib@free.fr

surgery, which is performed during the active phase of the disease (early surgery) in about half of patients with acute IE.⁴

Echocardiography has a known key role in the diagnosis of IE and the prediction of embolic risk. Moreover, echocardiography is also crucial for the prognostic assessment of patients with IE, for their follow-up under therapy, and during the perioperative period.⁵

Several guidelines have been proposed in the past few years concerning the prevention, diagnosis, and treatment of IE.^{6–10} In each of them, the value of echocardiography was clearly outlined. However, all previous recommendations suffer from several limitations. First, the respective indications of transthoracic (TTE) and transoesophageal (TEE) echocardiography, and the value of echocardiography in predicting embolic events, have been the source of conflicting publications and recommendations. Secondly, no previous recommendation has specifically addressed the role of echocardiography in IE.

The current 'recommendations for the practice of echocardiography in infective endocarditis' aims to provide both an updated summary concerning the value and limitations of echocardiography in IE, and clear and simple recommendations for the optimal use of both TTE and TEE in IE, assisting health care providers in clinical decision-making. These recommendations were obtained by expert consensus after thorough review of the literature available.

Chapter 1: Echocardiography for the diagnosis of infective endocarditis

1. When to perform echocardiography in infective endocarditis?

Infective endocarditis may be suspected in a variety of very different initial clinical situations,¹⁰ including heart failure, cerebral embolism, pacemaker (PM) infection, or isolated fever. Other situations requiring echocardiographic examination include fever associated with a regurgitant heart murmur, known cardiac disease, bacteraemia, new conduction disturbance, and embolic events of unknown origin.¹⁰ Finally, IE may be suspected both in very acute situations including cardiogenic or septic shock and in more insidious presentations. To avoid overuse of echocardiography, the decision to perform or not an echocardiographic examination must take into account the pre-test probability of the disease. Echocardiography should be performed in the clinical situations in which IE is suspected, as described in the ESC guidelines.¹⁰ However, whatever the level of suspicion, the most important issue is that, in all these situations, echocardiography must be performed as soon as possible in order to confirm or rule out the diagnosis of IE at the earliest opportunity.

2. Transthoracic or transoesophageal echocardiography in suspected infective endocarditis?

Figure 1 is an algorithm proposed by the recent Task Force on the Prevention, Diagnosis, and Treatment of Infective Endocarditis of the European Society of Cardiology,¹⁰ illustrating the respective

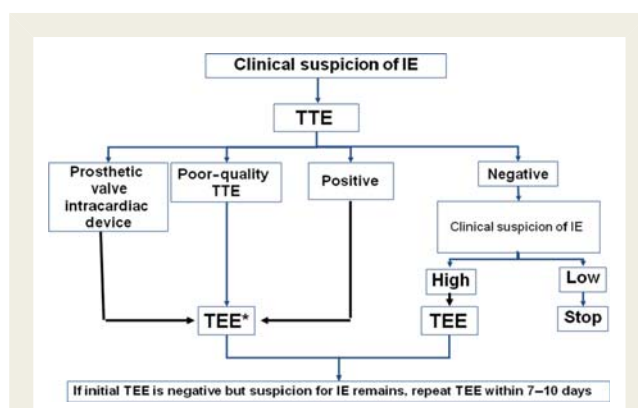


Figure 1 Algorithm showing the role of echocardiography in the diagnosis and assessment of infective endocarditis (adapted from Habib *et al.*¹⁰ with permission). IE, infective endocarditis; TTE, transthoracic echocardiography; TEE, transoesophageal echocardiography.

indications of TTE and TEE. Transthoracic echocardiography must be performed first in all cases, because it is a non-invasive technique that provides useful information for both the diagnosis and the assessment of IE severity. Transoesophageal echocardiography must also be performed in the majority of patients with suspected IE, because of its better image quality and better sensitivity, particularly for the diagnosis of perivalvular involvement. The only situation in which TTE may be considered sufficient is the case of good-quality negative TTE associated with a low level of clinical suspicion.

3. Anatomical features

Knowledge of the anatomical features of IE is fundamental in order to better understand, analyse, and describe the echocardiographic findings (Table 1). Anatomically, IE is characterized by a combination of vegetations, destructive lesions, and abscess formation.

- 3.1. Vegetations are typically attached on the low-pressure side of the valve structure, but may be located anywhere on the components of the valvular and subvalvular apparatus, as well as on the mural endocardium of the cardiac chambers or the ascending aorta. When large and mobile, vegetations are prone to embolism and less frequently to valve or prosthetic obstruction.
- 3.2. Destructive valve lesions are very frequently associated with vegetations or may be observed alone. They may provoke valve aneurysm, perforation or prolapse, and chordae or less frequently papillary muscle rupture. The usual final consequences of these lesions are severe valve regurgitation and heart failure.
- 3.3. The third main anatomical feature of IE is abscess formation. Abscesses are more frequent in aortic and prosthetic valve IE and may be complicated by pseudoaneurysm or fistulization.

These three anatomical features are frequently present together and must be meticulously described by the echocardiographic examination (Table 1).

Table 1 Anatomic and echocardiographic definitions (adapted from Habib et al.¹⁰ with permission)

	Surgery/necropsy	Echocardiography
Vegetation	Infected mass attached to an endocardial structure, or on implanted intracardiac material	Oscillating or non-oscillating intracardiac mass on valve or other endocardial structures, or on implanted intracardiac material
Abscess	Perivalvular cavity with necrosis and purulent material not communicating with the cardiovascular lumen	Thickened, non-homogeneous perivalvular area with echodense or echolucent appearance
Pseudoaneurysm	Perivalvular cavity communicating with the cardiovascular lumen	Pulsatile perivalvular echo-free space, with colour-Doppler flow detected
Perforation	Interruption of endocardial tissue continuity	Interruption of endocardial tissue continuity traversed by colour-Doppler flow
Fistula	Communication between two neighbouring cavities through a perforation	Colour-Doppler communication between two neighbouring cavities through a perforation
Valve aneurysm	Saccular outpouching of valvular tissue	Saccular bulging of valvular tissue
Dehiscence of a prosthetic valve	Dehiscence of the prosthesis	Paravalvular regurgitation identified by TTE/TEE, with or without rocking motion of the prosthesis

4. Echocardiographic criteria

In 1994, Durack proposed a new classification of IE (Duke criteria),¹¹ including, for the first time, echocardiography as a major criterion for IE. The major echographic criteria for IE are vegetation, abscess, and new dehiscence of a prosthetic valve (Figure 2).

4.1. Vegetation

The vegetation is the hallmark lesion of IE. Typically, vegetation presents as an oscillating mass attached to a valvular structure, with a motion independent to that of the valve (Figures 2A and 3). However, vegetations may also present as non-oscillating masses with atypical location (Figure 4A). The sensitivity of TTE for the diagnosis of vegetations is about 75%, but it may be reduced in case of low echogenicity, very small vegetations, and in IE affecting intracardiac devices or prostheses. Transoesophageal echocardiography enhances the sensitivity of TTE to about 85–

90% for the diagnosis of vegetations, while more than 90% specificity has been reported for both TTE and TEE.¹²

4.2. Abscess and perivalvular involvement

The second major echocardiographic criterion for endocarditis is the presence of a perivalvular abscess. Abscesses are more frequently observed in aortic valve IE and usually involve the mitral-aortic intervalvular fibrosa.¹³ They are also more frequent in prosthetic valve IE. Abscess typically presents as a perivalvular zone of reduced echo density, without colour flow detected inside. The diagnosis is easy in the presence of a clear free-space in the aortic root (Figure 2B), but may be much more difficult at the early stage of the disease when only a thickening of the aortic root is observed (Figure 4B). The sensitivity of TTE for the diagnosis of abscesses is about 50%, compared with 90% for TEE. Specificity higher than 90% has been reported, for both TTE and for TEE.¹⁴ Therefore, TEE needs to be performed in all cases of aortic valve IE and as soon as an abscess is suspected.¹⁴ However, small anterior abscesses are sometimes difficult to diagnose by TEE, and may be better evaluated by TTE. Consequently, both TTE and TEE are mandatory in suspected perivalvular involvement.

Other perivalvular complications include pseudoaneurysm and fistulization, which may both complicate the abscess formation. Pseudoaneurysm is characterized anatomically by a perivalvular cavity communicating with the cardiovascular lumen. The typical echographic appearance is that of a pulsatile perivalvular echo free-space with colour Doppler flow inside. Formation of a fistula may be a complication of both abscesses and pseudoaneurysm. It is anatomically defined by a communication between two neighbouring cavities and echographically by a colour Doppler communication between two adjacent cavities.

4.3. New dehiscence of a prosthetic valve

Dehiscence of a prosthetic valve represents the third main diagnostic criterion for IE.¹¹ Infective endocarditis must be suspected in the presence of new perivalvular regurgitation, even in the absence of a vegetation or abscess (Figure 2C). Transoesophageal echocardiography has a better sensitivity than TTE for this diagnosis, especially in mitral prosthetic valve IE.

4.4. Other echocardiographic findings in infective endocarditis

Other echocardiographic features are not main criteria for IE, but may be suggestive of the diagnosis. They include valve destruction and prolapse, aneurysm and/or perforation of a valve. The most frequent is anterior mitral valve leaflet perforation which is usually a complication of aortic valve IE. It may be observed either isolated or as a complication of a mitral valve aneurysm. Perforation of the mitral valve may be the consequence of a regurgitant jet through an infected aortic valve and is best visualized by TEE.¹⁵

In addition, both TTE and TEE are useful for the assessment of the underlying valve disease, and for the evaluation of consequences of IE, including:

- left ventricular size and function
- quantification of valve regurgitation/obstruction
- right ventricular function, estimation of pulmonary pressures
- presence and quantification of a pericardial effusion.

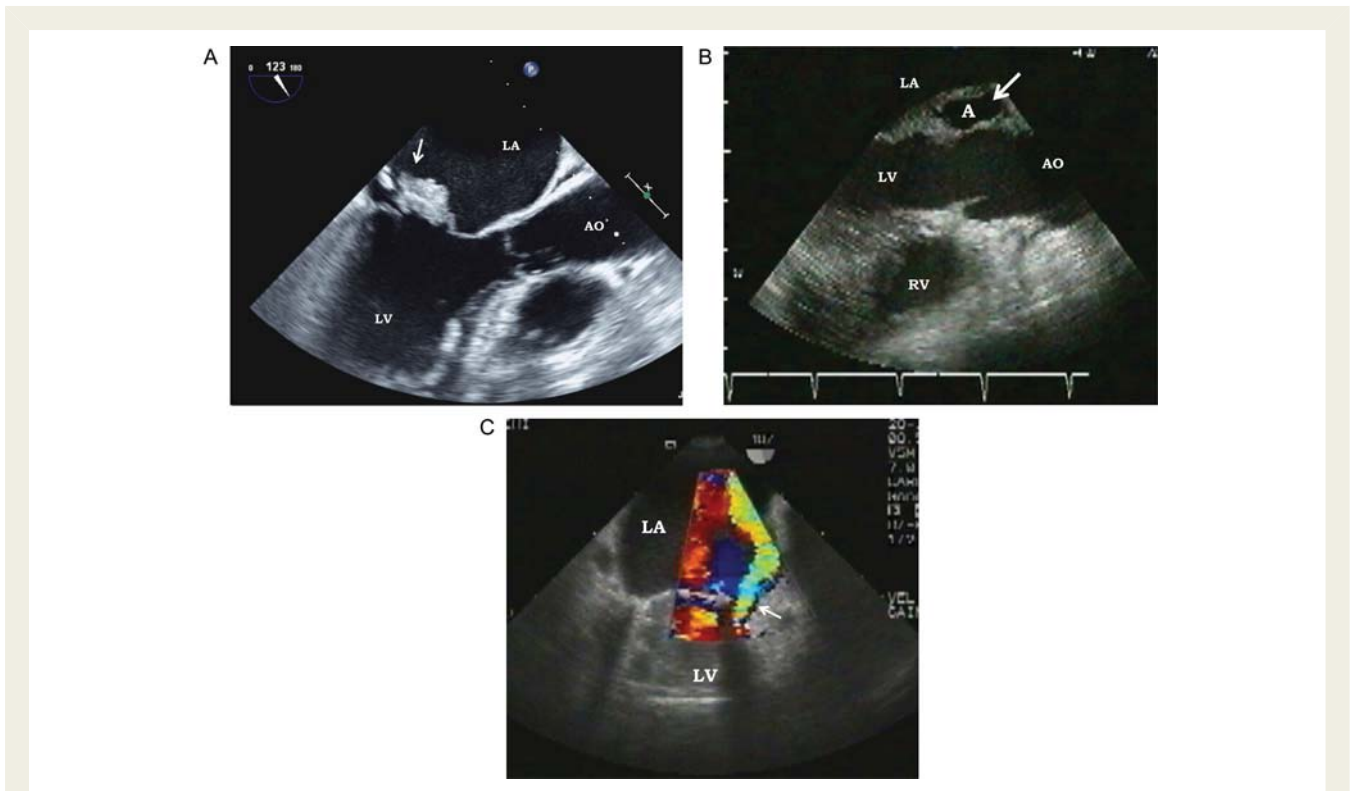


Figure 2 The three main echocardiographic criteria for endocarditis (TEE). (A) Large vegetation on the anterior mitral leaflet with chordae rupture (arrow). (B) Abscess: zone of reduced density (arrow) on the posterior part of the aortic root. (C) New prosthetic regurgitation (arrow) affecting a mechanical mitral prosthetic valve. LA, left atrium; LV, left ventricle; RV, right ventricle; Ao, aorta; A, abscess.

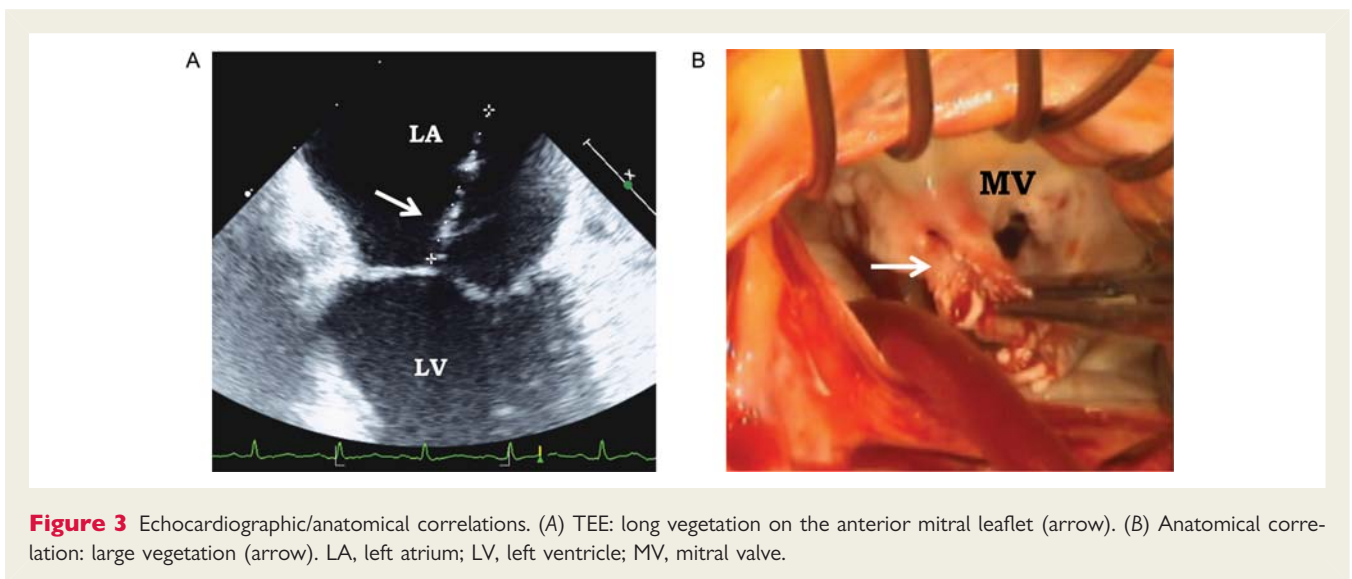


Figure 3 Echocardiographic/anatomical correlations. (A) TEE: long vegetation on the anterior mitral leaflet (arrow). (B) Anatomical correlation: large vegetation (arrow). LA, left atrium; LV, left ventricle; MV, mitral valve.

5. Limitations and pitfalls of echocardiography for the diagnosis of infective endocarditis

Although echocardiography plays a major role in the diagnosis of IE and gives a definite diagnosis of IE in a majority of patients, atypical or doubtful results are not rare, particularly at the early stage of the disease, and in patients with intracardiac materials (see Chapter 5).

The clinician must be aware that:

- (i) both the sensitivity and specificity of TTE and TEE are not 100%;
- (ii) a negative echocardiographic examination does not rule out IE;
- (iii) repeat TTE/TEE may be necessary in some situations;
- (iv) results of the echographic study must be interpreted with caution, taking into account the clinical presentation and the likelihood of IE.

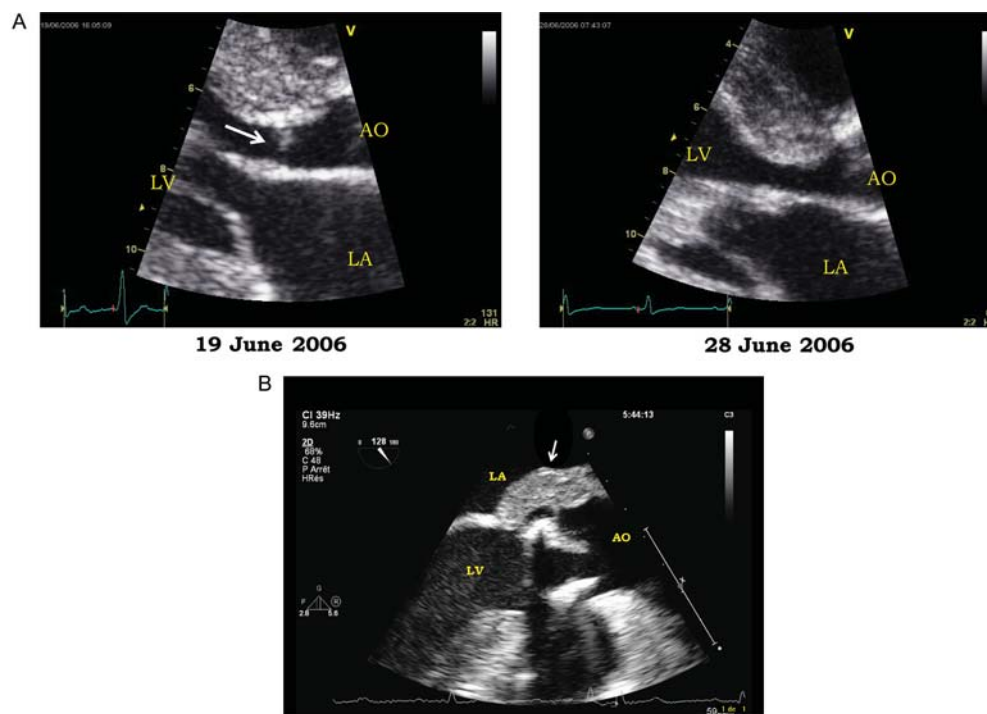


Figure 4 Difficult echocardiographic cases. (A) Left panel: small vegetation on the interventricular septum (arrow) in a patient with IE complicating a hypertrophic obstructive cardiomyopathy. Right panel: disappearance of the vegetation after antibiotic therapy. (B) Isolated thickening of the posterior part of the aortic root in a patient with a bioprosthetic aortic valve IE. LA, left atrium; LV, left ventricle; Ao, aorta.

1. Echocardiography is not 100% sensitive for the diagnosis of infective endocarditis

A negative echocardiogram may be observed in about 15% of IE. The most frequent explanations for a negative echocardiogram are very small vegetations and difficulties in identifying vegetations in the presence of pre-existent severe lesions (mitral valve prolapse, degenerative lesions, and prosthetic valves).¹⁶ Similarly, the diagnosis of IE may be more difficult when vegetations are non-oscillating and/or atypically located. In addition, the diagnosis may be difficult at the early stage of the disease, when vegetations are not yet present or too small to be identified.¹⁷ In one series¹⁸ of 105 patients with suspected IE, 65 cases had initial negative TEE and in 3 cases, vegetations appeared on a subsequent examination. For this reason,¹⁰ a normal echocardiogram does not completely rule out IE, even if TEE is performed and even in expert hands. A repeat examination has to be performed 7–10 days after the first examination in case of high level of clinical suspicion or even earlier when justified by the clinical presentation, for example in suspected postoperative staphylococcal prosthetic valve endocarditis (PVE). The additional diagnostic value of a third examination is very low.¹⁹

Similarly, the diagnosis of a perivalvular abscess may be difficult, even with the use of TEE, in case of small abscesses, when echocardiography is performed very early in the course of the disease, during the immediate postoperative period, or when the echogenicity is reduced by a prosthetic valve or severe valvular or perivalvular calcifications. Diagnosis of an abscess may be

particularly difficult in patients with abscess localized around calcification areas in the posterior mitral annulus.²⁰ Three-dimensional echocardiography may be useful in some situations (abscesses, mitral valve perforation), but brings little additional information when compared with conventional two-dimensional echocardiography.²¹

2. Echocardiography is not 100% specific for the diagnosis of infective endocarditis

Conversely, false diagnosis of IE may occur in several situations; for example, it may be difficult to differentiate between vegetations and thrombi, prolapsed cusp, cardiac tumours, myxomatous changes, Lambl's excrescences, strands, or non-infective vegetations (marantic endocarditis).¹⁶ Non-infective vegetations are impossible to differentiate from infective vegetations. They can be suspected in the presence of small and multiple vegetations, changing from one examination to another, and without associated abscess or valve destruction.

Key points

Both TTE and TEE are mandatory in the majority of patients with suspected or definite IE. The sensitivity and specificity of echocardiography are reduced in some subgroups, including PVE and patients with intracardiac devices. Echocardiography must be performed early, as soon as the diagnosis of IE is suspected and must be repeated in case of persisting high level of clinical

suspicion. All echographic results must be interpreted taking into account the clinical presentation of the patient.

Recommendations¹⁰

- (i) TTE is recommended as the first-line imaging modality in suspected IE;
- (ii) TEE is recommended in patients with high clinical suspicion of IE and a normal TTE;
- (iii) TEE should be considered in the majority of adult patients with suspected IE, even in cases with positive TTE;
- (iv) Repeat TTE/TEE within 7–10 days is recommended in case of initially negative examination when clinical suspicion of IE remains high;
- (v) TEE is not indicated in patients with a good-quality negative TTE and low clinical suspicion of IE.

Chapter 2: Echocardiography for the diagnosis and management of complications of infective endocarditis

Heart failure, perivalvular extension, and embolic events represent the three most frequent and severe complications of IE. They are also the three main indications for early surgery (i.e. while the patient is still receiving antibiotic treatment), which is performed in almost 50% of cases.^{4,10,22} Echocardiography, clearly the reference method for the diagnosis of vegetation, abscess, new regurgitation, or new prosthetic valve dehiscence, plays a key role in the diagnosis and management of these complications.

Echocardiography helps clinicians not only for taking the decision to operate or not, but also for choosing the optimal timing of surgery. The recent Task Force on the Prevention, Diagnosis, and Treatment of Infective Endocarditis of the European Society of Cardiology introduced this notion of timing of surgery and separated patients operated on as an emergency (within 24 h) or urgent (within a few days) basis, or later, after at least 1 or 2 weeks of antibiotic therapy¹⁰ (Table 2).

1. Heart failure/haemodynamic indications

Heart failure (HF) represents the most frequent (40–60% of cases) indication for surgery in IE.⁴ Recent European guidelines recommend early surgery to be performed in patients with acute regurgitation and HF, as well as in patients with obstructive vegetations.¹⁰ Echocardiography is useful in both situations.

Valve destruction causing acute regurgitation is the most characteristic lesion leading to HF in native valve IE.^{10,23,24} Echocardiography is mandatory as soon as symptoms or signs of HF occur, in order to determine the cause of HF and the haemodynamic tolerance. Rapid diagnosis and assessment of severity is fundamental, considering the high mortality risk of severe acute regurgitation unresponsive to medication without surgical treatment. A normal (or only slightly increased) left ventricular size and ejection fraction in the presence of severe aortic or mitral regurgitation is typical for acute regurgitation.^{23–25} However, in patients with history of

Table 2 Indications and timing of surgery in left-sided native valve infective endocarditis (adapted from Habib *et al.*¹⁰ with permission)

Recommendations: indications for surgery	Timing	Class ^a	Level ^b
(A) Heart failure			
Aortic or mitral IE with severe acute regurgitation or valve obstruction causing refractory pulmonary oedema or cardiogenic shock	Emergency	I	B
Aortic or mitral IE with fistula into a cardiac chamber or pericardium causing refractory pulmonary oedema or shock	Emergency	I	B
Aortic or mitral IE with severe acute regurgitation or valve obstruction and persisting heart failure or echocardiographic signs of poor hemodynamic tolerance (early mitral closure or pulmonary hypertension)	Urgent	I	B
Aortic or mitral IE with severe regurgitation and no HF	Elective	IIa	B
(B) Uncontrolled infection			
Locally uncontrolled infection (abscess, false aneurysm, fistula, enlarging vegetation)	Urgent	I	B
Persisting fever and positive blood cultures >7–10 days	Urgent	I	B
Infection caused by fungi or multiresistant organisms	Urgent/ elective	I	B
(C) Prevention of embolism			
Aortic or mitral IE with large vegetations (>10 mm) following one or more embolic episodes despite appropriate antibiotic therapy	Urgent	I	B
Aortic or mitral IE with large vegetations (>10 mm) and other predictors of complicated course (heart failure, persistent infection, abscess)	Urgent	I	C
Isolated very large vegetations (>15 mm) ^c	Urgent	IIb	C

Emergency surgery: surgery performed within 24 h; urgent surgery: within a few days; elective surgery: after at least 1 or 2 weeks of antibiotic therapy.

^aClass of recommendation.

^bLevel of evidence.

^cSurgery may be preferred if procedure preserving the native valve is feasible.

chronic regurgitation, the left ventricle may be enlarged. Two-dimensional echocardiography combined with pulsed, continuous, and colour Doppler enable (i) a detailed assessment of the mechanism (valve perforation, cusp fenestration, torn leaflet, flail mitral leaflet due to ruptured infected chordae, or interference of the vegetation mass with leaflet closure) and (ii) a reliable quantification and evaluation of the haemodynamic tolerance of

the regurgitation (cardiac output, left and right ventricular filling pressures, pulmonary arterial pressure, left and right ventricular function).^{10,24} Some echocardiographic findings, such as extensive destructive valve lesions, massive regurgitation, or associated abscess or pseudoaneurysm, suggest the need for early surgery (Figure 5). Due to rapid elevation of the left ventricular end-diastolic pressures, premature mitral valve closure associated with short pressure half-time of the aortic regurgitant flow (<200 ms) and restrictive mitral inflow may be observed in acute severe aortic regurgitation,^{5,10,24,27,28} also suggesting the need for surgery. In aortic IE with aortic regurgitation, a secondary infection of the ventricular surface of the anterior mitral leaflet may occur (jet lesion), resulting in the formation of an aneurysm that may lead to the perforation of the anterior mitral leaflet (Figure 6) and to consequent mild-to-severe acute mitral regurgitation.^{25,26,29} Mitral valve aneurysms appear on two-dimensional echocardiography as a bulge of the anterior leaflet protruding into the left atrium (Figure 7). Transthoracic echocardiography and TEE are the procedures of choice for diagnosis of mitral valve aneurysm and perforation. Careful echocardiographic examination of the mitral leaflets is required in all patients with aortic IE, because small aneurysms or perforations may be easily missed.

Less frequently, HF may be due to obstructive vegetations resulting in functional valve stenosis or due to intra-cardiac shunts generally associated with major destructive lesions.¹⁰ In

cases with obstructive vegetations resulting in HF, two-dimensional echocardiography visualizes the mass that partially obstructs the valve orifice. Elevated transvalvular gradients and reduced orifice area can be measured with Doppler echocardiography.

Finally, HF may be due to myocarditis or myocardial infarction. Echocardiography allows the evaluation of global and regional left and right ventricular function and identifies these complications.

When surgery has not been performed on an urgent basis, patient must be closely followed-up by repeated echocardiographic examinations in order to detect new worsening of cardiac lesions.

Key points

Heart failure is the most frequent and severe complication of IE. Urgent TTE is required as soon as symptoms or signs of HF are detected. It has a primary role in determining the cause of HF and in the evaluation of the haemodynamic status. Transoesophageal echocardiography should be widely performed to better analyse the lesions, especially in cases with inconclusive TTE.

2. Perivalvular extension/infectious indications

These represent the second most frequent indication for early surgery in Europe.⁴ In the European guidelines, the infectious

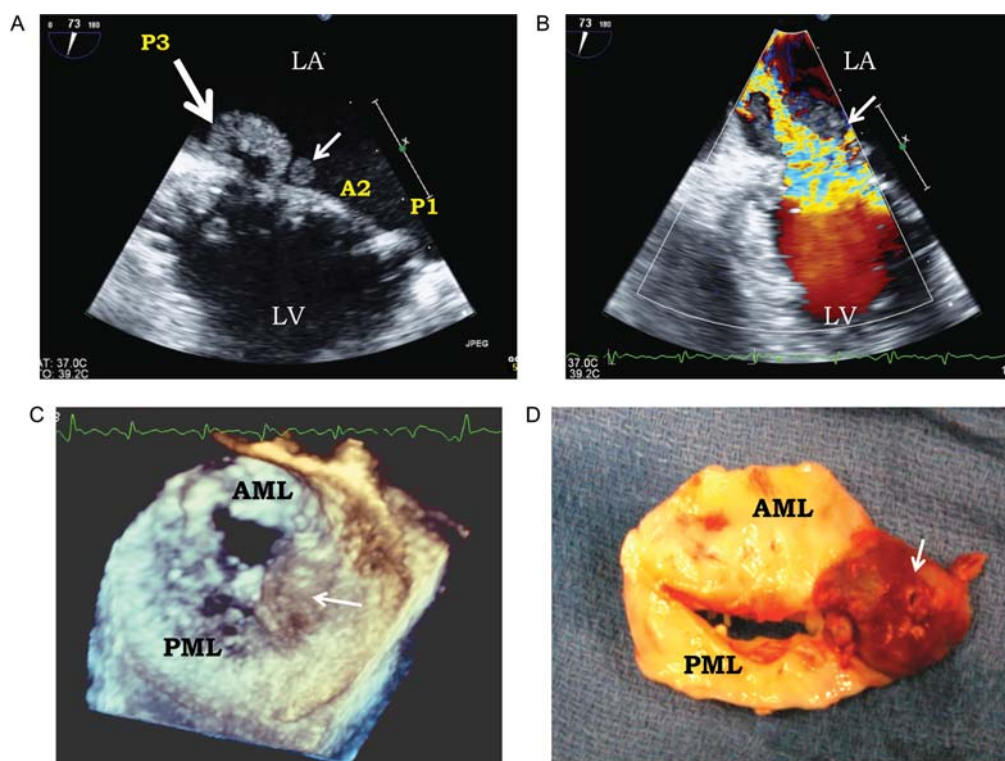


Figure 5 Severe native valve IE with commissural abscess and perforation. (A) Vegetation and pseudoaneurysm (thick arrow) of the posterio-internal commissure of the mitral valve, associated with a small vegetation (thin arrow). (B) Fistulization of the pseudoaneurysm into the left atrium causing massive mitral regurgitation (arrow). (C) Three-dimensional echocardiography showing the commissural abscess (arrow). (D) Anatomical correlation: surgical specimen showing the commissural abscess (arrow). LA, left atrium; LV, left ventricle; AML, anterior mitral leaflet; PML, posterior mitral leaflet.

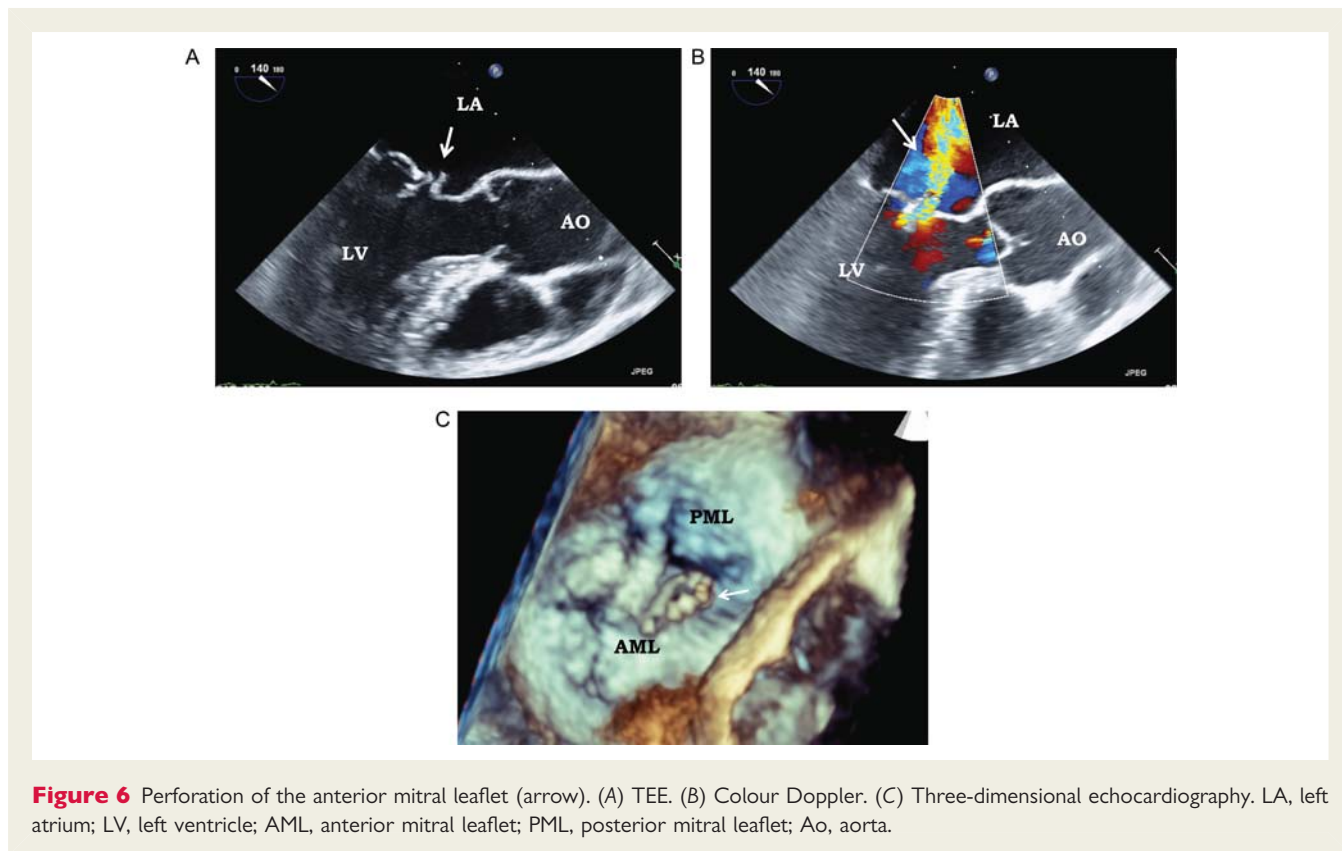


Figure 6 Perforation of the anterior mitral leaflet (arrow). (A) TEE. (B) Colour Doppler. (C) Three-dimensional echocardiography. LA, left atrium; LV, left ventricle; AML, anterior mitral leaflet; PML, posterior mitral leaflet; Ao, aorta.

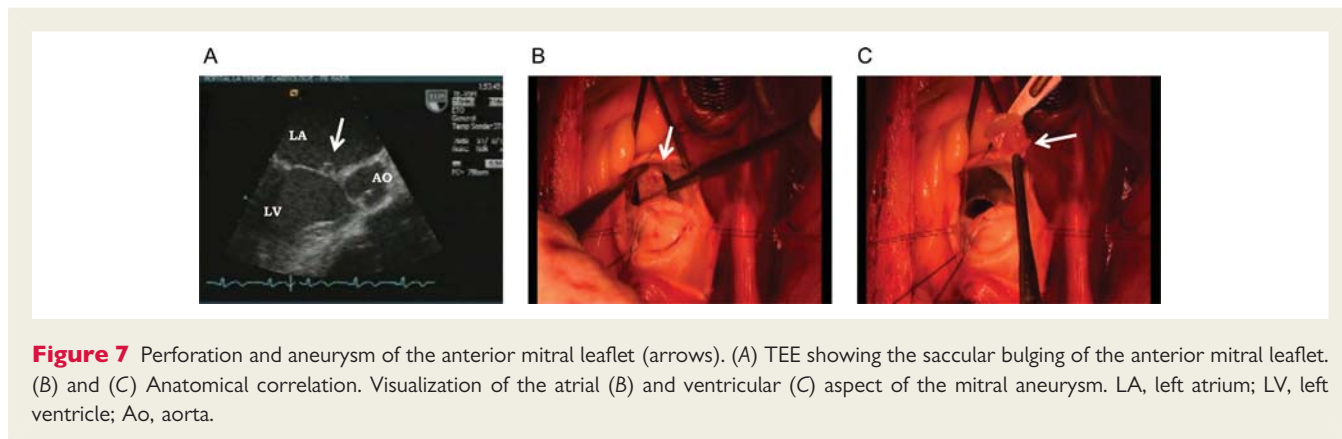


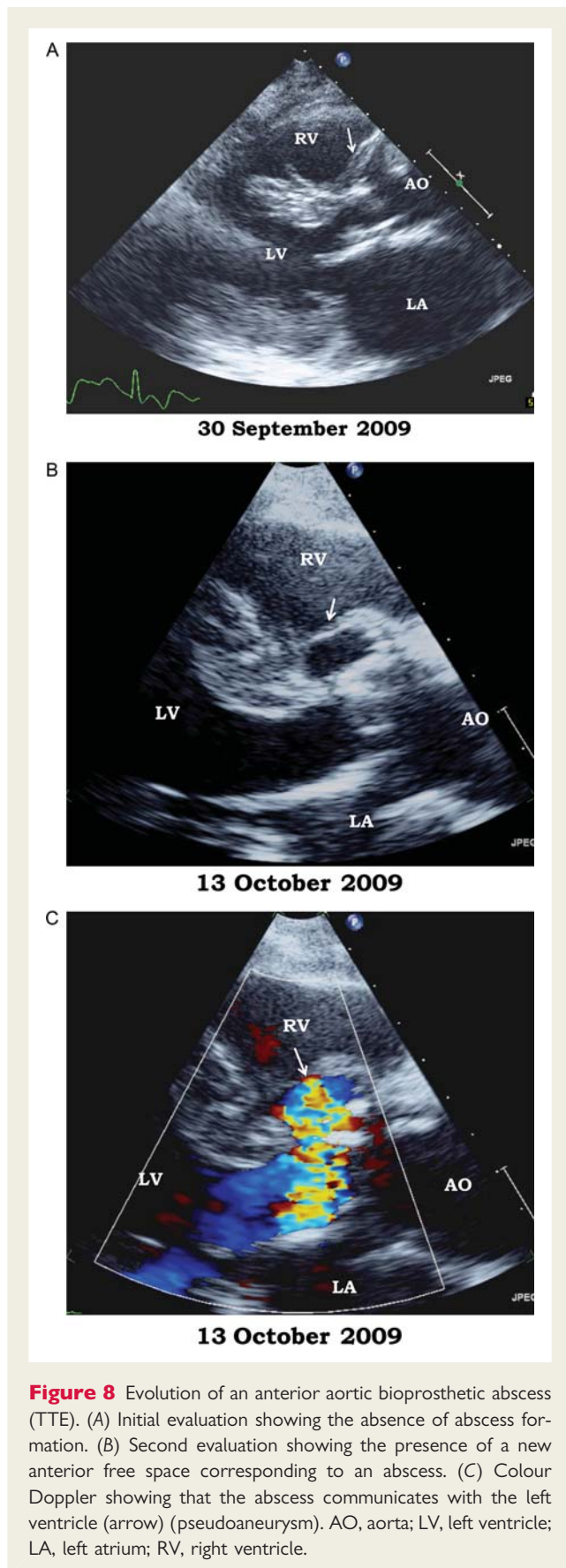
Figure 7 Perforation and aneurysm of the anterior mitral leaflet (arrows). (A) TEE showing the saccular bulging of the anterior mitral leaflet. (B) and (C) Anatomical correlation. Visualization of the atrial (B) and ventricular (C) aspect of the mitral aneurysm. LA, left atrium; LV, left ventricle; Ao, aorta.

complications needing surgery include locally uncontrolled infection, persistent fever, and infection caused by fungi or multiresistant organisms.¹⁰ Echocardiography plays a key role in the assessment of perivalvular lesions, including abscess, pseudoaneurysm, and fistula.

Echocardiographic presentation of perivalvular lesions is described in Chapter 1. Abscess formation in aortic IE is a dynamic process starting with aortic root wall thickening.³⁰ When a slight thickening of the aortic root is visualized, the diagnosis of abscess should be suspected and echocardiography repeated. The diagnosis is confirmed when the lesion progresses, leading to the formation of an abscess or a pseudoaneurysm (Figure 8). Extensive tissue destruction may also result in the formation of fistulae.^{31–33} Perivalvular extension may also be

discovered on systematic TEE. Finally, TEE allows an accurate assessment of the site and dimensions of abscesses or pseudoaneurysms.²² Transthoracic echocardiography and TEE combined with pulsed, continuous, and colour Doppler are the techniques of choice for the diagnosis and localization of fistulae and the quantification of the resulting intra-cardiac shunts. Computed tomography (CT) scan has been shown to give useful complementary information for the assessment of the perivalvular extent of abscesses and pseudoaneurysms.¹⁰

Unless severe comorbidities are present, surgery must be performed on an urgent basis when a perivalvular complication is diagnosed by echocardiography.¹⁰ However, in a minority of patients characterized by rapid and favourable response to antibacterial



therapy with small and stable abscesses, a conservative treatment may be discussed.^{22,34,35} A conservative approach might be an option for patients with non-Staphylococcal IE without heart failure, heart block, severe valvular regurgitation, or dehiscence.^{10,22,34} Close clinical and biological monitoring and serial TEE are mandatory in this rare situation.³⁴ Conversely, emergency surgery may be necessary because of extensive perivalvular lesions associated with severe heart failure.

Vegetations with increasing dimension on serial TEE examinations in a patient with adapted antibacterial therapy are a sign of uncontrolled infection and represent another indication for surgery.¹⁰ Transoesophageal echocardiography is the method of choice for measuring the size of the vegetation and for follow-up.¹

Key points

Prompt TTE and TEE in IE are required in cases of uncontrolled infection and in patients at risk for perivalvular extension. Transoesophageal echocardiography is the technique of choice for the diagnosis of perivalvular extension and its resulting complications.

3. Embolic events/embolic indications

Vegetations or fragments of vegetation may embolize via the vascular bed, resulting in embolic events. This is a common complication of IE occurring in 20–50% of patients^{10,36–40} and carries a high risk of morbidity and mortality.¹⁰ The most frequent sites of embolism in left-sided IE are the brain and spleen while pulmonary embolism is frequent in native right-sided and PM lead IE. Embolic events may be totally silent in about 20% of IE patients, especially those affecting the splenic or cerebral circulation,³⁷ and must be diagnosed by systematic non-invasive imaging

Embolism may occur before diagnosis as well as after diagnosis during antibacterial therapy, while it is rare after the completion of antibacterial therapy. Since echocardiography is the procedure of choice for the diagnosis of vegetations (Section 1), TTE and particularly TEE should be performed in case of occurrence of any embolic event. Echocardiography assesses the number, size, shape, location, echogenicity, and mobility of vegetations.^{37,40–44} Echocardiography is useful for predicting embolic risk and therefore plays a key role in identifying a subgroup of patients who might benefit from early surgery to avoid embolism.^{40–46} Indeed, some echocardiography characteristics of vegetations are associated with an increased embolic risk. The size and mobility of vegetations are powerful echocardiographic predictors of new embolic events.⁴⁰ Patients with vegetations greater than 10 mm are at higher risk of embolism (Figure 9). This risk is even higher in patients with very large (>15 mm) and mobile vegetations.^{37,40,42} Thus, careful measurement of the maximal vegetation size at time of diagnosis and during follow-up is strongly recommended as part of the risk stratification. Moreover, embolism occurs more frequently in patients with vegetations located on the mitral valve (in particular on the anterior mitral leaflet) and when increasing or decreasing size of the vegetation is observed under antibiotic therapy.^{36,41–43} However, the ability of echocardiography to predict the individual patient risk for embolism remains limited.^{10,22} Actually, echocardiographic findings are not the sole predictors of the occurrence of an embolic event.

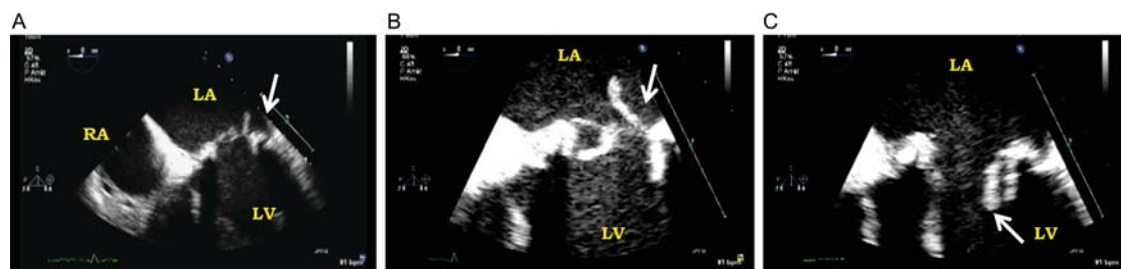

Figure 9 Transoesophageal echocardiography showing a large and mobile vegetation (arrows) on a bioprosthetic mitral valve moving from the left atrium (A and B) to the left ventricle (C) through the prosthesis. LA, left atrium; LV, left ventricle; RA, right atrium.

Other factors (i.e. biologic factors, specific microorganisms) play a significant role.^{10,37} Importantly, the risk of new embolism is highest during the first days after the initiation of antibacterial therapy and the rate of new embolic events drops dramatically after the first 2 weeks of antimicrobial therapy, although some risk persists when vegetations remain present.^{38,41,45} For this reason, the benefits of surgery to prevent embolism are greatest during the first week of antibiotic therapy.¹⁰

The Task Force on the Prevention, Diagnosis, and Treatment of Infective Endocarditis of the European Society of Cardiology¹⁰ recommends surgery to be performed when a large vegetation (>10 mm) is present following one or more embolic episodes. In addition, when associated with known other predictors of a complicated course (heart failure, persistent infection under therapy, abscess, and prosthetic endocarditis), the presence of a large vegetation (>10 mm) indicates an earlier surgical decision. Finally, the decision to operate early in isolated very large vegetation (>15 mm) is more difficult and must be specific for the individual patient. Surgery may be preferred when a valve repair seems possible, particularly in mitral valve IE. Finally, as far as prevention of embolism is concerned, surgery, when considered, must be performed on an urgent basis.

Key points

Embolism is a common and severe complication of IE, complicating 20–50% of cases of IE. The risk of embolism is highest during the first 2 weeks of antibiotic therapy and is clearly related to the size, location, and mobility of the vegetation. The highest risk is observed for large (>10–15 mm) and very mobile vegetations. Echocardiography, particularly TEE, is the key examination for the diagnosis and description of characteristics of vegetations. The decision to operate early to prevent embolism depends on several factors, including size and mobility of the vegetation, previous embolism, type of microorganism, and duration of antibiotic therapy. The occurrence of embolic events requires systematic TTE and TEE examination.

4. Other complications

Pericarditis: Purulent pericarditis is rare. Infection involving the mitral or tricuspid annulus may extend to the pericardium. Purulent pericarditis may also be secondary to a pseudoaneurysm of

the proximal aorta, a myocardial abscess, a myocarditis, or a septic coronary-embolus. Rarely, ruptured pseudoaneurysms or fistulae may communicate with the pericardium, with dramatic and often fatal consequences. Echocardiography is the best examination to diagnose and appreciate the haemodynamic tolerance of pericarditis and may guide drainage.

Coronary obstruction: In the rare cases of coronary obstruction due to vegetation embolism, coronary compression, or ostial occlusion by large vegetation, echocardiography may visualize a new left ventricular segmental wall motion abnormality.

Myocarditis: Myocarditis is an uncommon complication of IE, generally associated with abscess formation. Transthoracic echocardiography plays a key role for the evaluation of global and regional left and right ventricular function in this situation.

Key points

In summary, HF, perivalvular infection, and high embolic risk are the three main indications for early surgery. Echocardiography plays a major role in decision-making in IE when one of these three situations occurs. The presence of HF, abscess, or high embolic risk usually indicates urgent surgery.

Chapter 3: Echocardiography for the follow-up and prognostic assessment of IE

Despite diagnostic and therapeutic advances, mortality is still high in IE. Overall mortality for left-sided IE is 20–25%.⁴⁷ It is lower for right-sided IE in intravenous drug abusers (IVDA; 4–10%.^{48,49} Echocardiography (TTE and TEE) is an invaluable adjunct to clinical decision-making concerning potential surgical intervention and prediction of short- and long-term prognosis. The role of echocardiography in this setting can be separated into three different evolving periods of the disease: at admission to the hospital, during hospitalization, and after discharge.

1. Prognostic assessment at admission

Prognosis in IE is influenced by four main factors: the patient's clinical characteristics, the presence or absence of cardiac and non-cardiac complications, the type of infecting microorganism, and the echocardiographic findings. Patients with heart failure,

perivalvular complications, and/or *Staphylococcus aureus* infection are at highest risk of death and need for surgery in the active phase of the disease.⁵⁰ Several echocardiographic features have been associated with a worse prognosis, including perivalvular complications, severe native or prosthetic valve regurgitation or obstruction, low left ventricular ejection fraction, pulmonary hypertension, large vegetations, and premature mitral valve closure or other signs of elevated diastolic pressures.

Thus, echocardiography plays an essential role both in diagnostic and prognostic assessment of patients with IE. In addition, echocardiography is also useful to predict the risk of new embolism.^{40,41}

2. Echocardiographic follow-up under therapy

Echocardiography must be used for follow-up of patients with IE under antibiotic therapy, along with clinical follow-up. The number, type, and timing of repeat examinations depend on the clinical presentation, the type of microorganism, and the initial echographic findings. Weekly TTE may be sufficient in non-complicated streptococcal native IE, while more frequent TEE and TTE controls can be necessary in postoperative staphylococcal early PVE. During hospitalization, serial echographic studies may show a gradual reduction in size, decrease in mobility, and increase in echogenicity of vegetations. However, these lesions may either disappear or remain unchanged long after the acute phase of the disease, even after healing of the disease. In one study, failure to decrease vegetation size with antibiotic treatment was associated with an increased risk of embolism.³⁶ Conversely, Vilacosta et al.⁴¹ showed that most vegetations (83.8%) remains constant in size under therapy, and that this does not worsen prognosis. However, in this study, both increase of vegetation size under antibiotic therapy (observed in 10.5% of patients with IE) and reduction of vegetation size under therapy were associated with an increased embolic risk. Thus, increasing vegetation size under therapy must be considered as a risk factor for new embolic event, while unchanged or reduced vegetation size under therapy may be more difficult to interpret.¹⁰

3. Follow-up after discharge and long-term prognosis

After hospital discharge, the main complications include recurrence of infection, HF, need for valve surgery, and death. Embolization is rare. The 6-month mortality rate in IE is between 22 and 27%.^{3,51–53} The risk of recurrence is low (1.3–6.6% in two recent series^{54,55}) but is higher in patients with PVE, perivalvular extension, and IVDA. Similarly, the risk of HF and need for late surgery is low after discharge, but is higher in patients with perianular extension and persisting valve regurgitation.

For these reasons, both clinical and echocardiographic follow-up are recommended after discharge. To monitor the development of secondary HF, the recent ESC guidelines¹⁰ recommend performing an initial baseline TTE at the completion of antimicrobial therapy, and serial examinations at 1, 3, 6, and 12 months during the first year following completion of therapy. Repeat TEE is usually not necessary after discharge, except in selected patients with incomplete surgical treatment or persistent valve or prosthetic

dysfunction. After discharge, recommendations for surgery are those of conventional valvular guidelines.

Key points

In association with clinical and microbiological parameters, echocardiography is helpful for rapid prognostic assessment at admission and should be used to choose the best therapeutic option. Transthoracic echocardiography and/or TEE are useful for follow-up of patients with IE under therapy.

Recommendations¹⁰

- (1) Repeat TTE and TEE are recommended as soon as a new complication of IE is suspected and should be considered during follow-up of uncomplicated IE, in order to detect new silent complications and monitor vegetation size.**
- (2) TTE is recommended before discharge for subsequent comparison.**
- (3) Clinical and echocardiographic periodic follow-up is mandatory during the first year after the end of antibiotic treatment.**

Chapter 4: Intraoperative echocardiography

Although few data in IE patients are available on the impact of systematic use of intraoperative TEE,⁵⁶ the Task Force on the Prevention, Diagnosis, and Treatment of Infective Endocarditis of the European Society of Cardiology recommends intraoperative TEE to be performed in all cases of IE requiring surgery.¹⁰ In fact, intraoperative TEE in this setting may provide additional diagnostic information before bypass, is able to assess the adequacy of the surgical procedure before the chest is closed, and therefore may modify the operative plan.

In IE, meticulous echocardiographic evaluation, generally including TEE, is systematically performed to select patients referred for surgery. Nevertheless, infective lesions may progress since the last preoperative examination. Vegetations may grow or embolize.⁵⁶ The infectious process may rapidly extend to form or worsen abscess and/or fistulous tracts or to involve other valves. Thus, a pre-pump TEE in the operative room allows a final evaluation of valvular and perivalvular lesions. This exam may provide new data on the extent of the infectious process and valve reparability, and therefore confirm or modify the operative plan. In a recent series, systematic pre-pump intraoperative TEE changed the initial operative plan in 11% of cases.⁵⁶ Pre-pump TEE is particularly helpful to determine the best surgical approach by identifying the mechanism of regurgitation (i.e. valve repair or valve replacement) and the extension of the lesions outside the valve tissue.^{56–58}

Post-pump intraoperative TEE is fundamental in the evaluation of the immediate surgical result in patients with infected and friable tissues, especially to assess the result of valve repair (highly sensitive to detect a significant residual regurgitation), valve replacement (analysis of prosthesis function, detection, localization, and quantification of perivalvular leaks), and complex

perivalvular repair.^{56,58} Immediate reoperation may be undertaken based on TEE findings, in a percentage of cases reaching 10% when using systematic intraoperative TEE.⁵⁶ Yet, the role of the surgeon to ascertain macroscopic eradication of all infected tissue remains fundamental because intraoperative TEE is not sensitive enough to identify all foci of residual infection. Post-pump intraoperative TEE also serves as a reference document of the surgical result for subsequent post-operative echocardiography. In addition, a post-pump intraoperative TEE also helps in the assessment and treatment of difficult weaning from the cardiopulmonary bypass pump and can guide difficult de-airing.⁵⁶

Key points

Intraoperative TEE in IE may provide useful data for the planning of surgery, is essential for the immediate quality control of the operative procedures, has the potential to improve surgical results, and is a reference for future studies. A wide experience and a high degree of expertise are required to perform this examination that guides the surgeon and may change the course of operation. The impact of intraoperative TEE leads to recommend its routine and systematic use, especially in cases of conservative valve surgery and other complex procedures.

Recommendation:

Intraoperative TEE is recommended in all patients with IE undergoing cardiac surgery.

Chapter 5: Echocardiography in specific clinical conditions

1. Prosthetic valve infective endocarditis

Incidence and pathophysiology

Prosthetic valve endocarditis is the most severe form of IE and occurs in 1–6% of patients with valve prostheses,^{59–64} accounting

for 10–30% of all cases of IE⁶⁰ with similar incidences observed in mechanical and bioprosthetic valves.

The pathophysiology of PVE differs from that of native valve endocarditis (NVE) in several aspects. Prosthetic valve endocarditis is characterized by a lower incidence of vegetations and higher incidence of abscesses and perivalvular complications.⁶⁰ The anatomical involvement differs between PVE affecting mechanical vs. bioprosthetic valves.⁶¹ In mechanical valves, the infection usually involves the junction between the sewing ring and the annulus, leading to perivalvular abscess, dehiscence, pseudoaneurysms, and fistula. In bioprosthetic IE, infection is more frequently located on the leaflets, leading to cusp rupture, perforation, and vegetations.

The usual consequence of PVE is new prosthetic regurgitation causing heart failure. Less frequently, large vegetations may cause prosthetic valve obstruction.

Echocardiographic findings

Although fluoroscopy is valuable in the setting of PVE, echocardiography, particularly TEE, plays the key role in the diagnosis and evaluation of these patients. Both the anatomical lesions and their haemodynamic consequences can be completely evaluated by Doppler echocardiographic techniques. Transoesophageal echocardiography is mandatory in PVE because of its better sensitivity and specificity for the detection of vegetations, abscesses, and perivalvular lesions in this setting.⁶⁵

However, the value of both TTE and TEE is lower in PVE than in NVE for several reasons. First, the presence of intracardiac material may hinder the identification of both vegetations and abscesses, explaining the lower sensitivity of TEE in PVE when compared with NVE. Consequently, a negative echocardiogram is relatively frequently observed in PVE,¹⁷ and does not rule out the diagnosis of IE. Repeat examination must be performed if clinical level of suspicion is still high (*Figure 10*).¹⁷ Secondly, it may be difficult to differentiate between thrombus or strand and a vegetation (*Figure 11*) and between bioprosthetic degeneration and

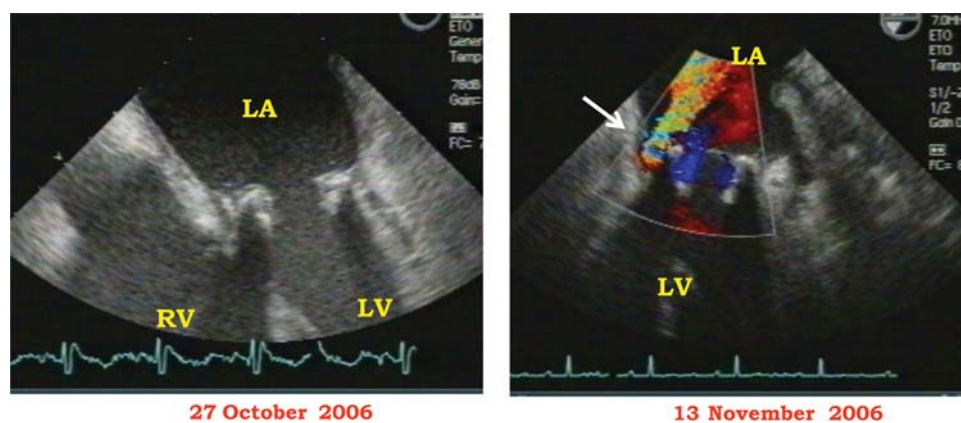


Figure 10 Evolution of a mitral bioprosthetic valve endocarditis. Left panel: initial evaluation showing an apparently normal bioprosthetic. Right panel: second evaluation performed because of persistent fever, showing the presence of a new periprosthetic mitral regurgitation (arrow). LV, left ventricle; LA, left atrium; RV, right ventricle.

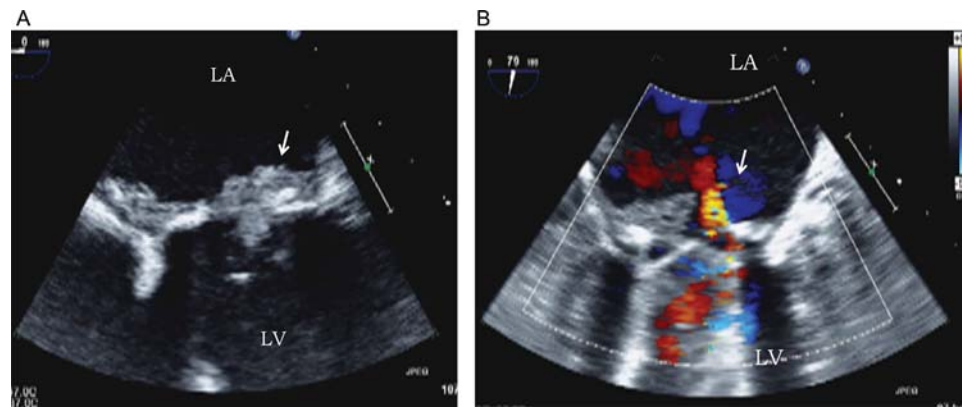


Figure 11 Mitral prosthetic valve endocarditis with prosthetic obstruction (transoesophageal echocardiography). (A) Large vegetation prolapsing into the mitral mechanical prosthetic valve (arrow). (B) Central regurgitation associated with the absence of the physiological regurgitant jets (arrow). LV, left ventricle; LA, left atrium; RV, right ventricle.

infective lesions. Thirdly, the diagnosis of an abscess is frequently more difficult in PVE, particularly in the early postoperative period after valve replacement. For example, a thickening of the aortic root is frequently observed after a Bentall procedure, mimicking abscess formation despite the absence of IE. Finally, a new dehiscence of a prosthetic valve represents the third main diagnostic criterion for IE.¹¹ Infective endocarditis must be suspected in the presence of a new periprosthetic regurgitation, even in the absence of a vegetation or abscess. Transoesophageal echocardiography has a better sensitivity than TTE for this diagnosis, especially in mitral PVE. However, the diagnostic value of a prosthetic regurgitation depends on knowing of a previous normal TEE examination. For this reason, systematic postoperative echocardiography must be performed after any valve replacement in order to serve as reference for better interpretation of future echocardiographic abnormalities. As a consequence of these limitations, the Duke criteria have a lower sensitivity for the diagnosis of PVE, when compared with native valve IE.^{66,67}

Role of echocardiography during treatment and follow-up of prosthetic valve endocarditis

As in NVE, echocardiography plays a key role in the prognostic assessment of PVE. The presence of severe prosthetic regurgitation or obstruction (*Figure 11*), periprosthetic complications, and large vegetations (*Figure 9*) are associated with poor outcome in PVE and indicates the need for surgery in the majority of patients, unless comorbidities are too severe. In these patients with frequently severely destructive lesions, intraoperative echocardiography is mandatory, particularly in cases of homograft surgery. In non-complicated PVE treated medically, repeat echocardiographic examinations are necessary, in order to detect progressive prosthetic dysfunction.

Key points

Prosthetic valve endocarditis represents one of the most frequent and severe form of IE. Both TTE and TEE are mandatory in suspected or definite PVE. Perivalvular

complications are most frequent in aortic PVE, and are better assessed by TEE. However, the sensitivity and specificity of both TTE and TEE are lower in PVE than in NVE. Echocardiography is also recommended for the preoperative and postoperative assessment of operated patients and for the follow-up of patients treated by medical therapy alone, because of the risk of late prosthetic dysfunction.

2. Cardiac device-related infective endocarditis

Infections of cardiac devices, including permanent PMs and implantable cardioverter defibrillators (ICDs), are associated with substantial morbidity, mortality, and financial cost. Echocardiography has a key role in the diagnosis and assessment of patients with this condition.

Incidence and pathogenesis

The reported incidence of infection of these devices varies widely among studies. A recent population-based study found an incidence of 1.9 per 1000 device-years.⁶⁸ The probability of infection is higher after ICD implantation when compared with a PM implantation.^{68,69} Local device infection has to be distinguished from cardiac device-related infective endocarditis (CDRIE); the former is defined as an infection limited to the pocket of the device and should clinically be suspected in the presence of local signs of inflammation at the generator pocket. On the contrary, CDRIE refers to an infection extending to the electrode leads, valvular apparatus, or endocardial surface. However, differentiating both entities is not always possible.^{69,70} The main pathogenetic mechanism of CDRIE is contamination by local bacteriological flora at the time of device implantation, replacement, or any other sort of manipulation.⁷¹

Echocardiographic findings

Echocardiography plays a key role in CDRIE and is the technique of choice for the detection and sizing of vegetations. Vegetations may

be attached to the electrode lead, the tricuspid leaflets, and to the endocardial wall. In addition, this technique will be useful in the evaluation of tricuspid regurgitation, assessment of right heart chamber dilatation, and quantitation of pulmonary artery pressure. Since vegetations can be found anywhere from the superior vena cava to the right ventricle, echocardiography should evaluate the whole infectious lead course. In addition, assessment of the other heart valves, native and prosthetic, is important. In most patients, vegetations attached to the electrode lead present with a typical motion and morphology (Figure 12A), and are a major criterion for IE. In other cases, lead vegetations may have a sleeve-like appearance⁷² and are difficult to distinguish from thrombi (Figure 12B). In this situation, the clinical scenario and a new echocardiogram may help the diagnosis. Transthoracic echocardiography has a poor sensitivity and negative predictive value for the detection of cardiac device vegetations. Transoesophageal echocardiography has a higher sensitivity and specificity than TTE,^{73,74} but both modalities must be performed for a complete evaluation of patients' condition.

Difficulties in the detection of lead vegetations by TTE are explained by the following reasons: presence of reverberation lead echoes, especially in patients with more than one intracardiac lead, atypical location of vegetations (within the superior vena cava or in the right atrium), and inadequate transthoracic acoustic window of these usually older patients.^{73,74} Transthoracic echocardiography and TEE may be falsely negative. Therefore, a normal echographic examination does not rule out CDRIE. When clinical suspicion of CDRIE is high and results from TEE are negative, a repeat TEE is warranted within 7 days.

The Duke criteria are difficult to apply in these patients because of lower sensitivity. Modifications of these criteria have been proposed, to include local signs of infection and pulmonary embolism as major criteria.^{72,75} Lung CT and lung scintigraphy may be used to assess the presence of pulmonary embolism. Septic pulmonary embolism before extraction of the infected material is common, but its clinical impact is usually low.^{72,75} The risk of pulmonary embolism is related to the size of vegetation.

Preliminary experience with intracardiac echocardiography has been reported.⁷⁶

Management

Cardiac-device related infective endocarditis must be treated with prolonged antibiotic therapy as well as device removal.⁶⁹ Results of echocardiographic examination have been reported to influence the mode of device removal, some authors recommending surgery to be performed in patients with very large vegetations.^{70,77} However, in most cases, device extraction may be performed percutaneously without need for surgery, even in cases of large vegetations, since overall risks are even higher with surgical extraction.⁶⁹ Surgery may only be considered with very large vegetations (>25 mm). Echocardiography (TTE and/or TEE) should be repeated after device extraction, and the existence of residual vegetations and tricuspid valve lesions ruled out. Careful examination of the right ventricle, tricuspid valve, right atrium, and distal superior vena cava is essential.^{73,74}

Key points

Although TEE is superior to TTE, both are mandatory in suspected or definite CDRIE, but their sensitivity and specificity are lower than in native IE. Echocardiography is also useful for the measurement of vegetation size and should be repeated after device extraction.

3. Right heart infective endocarditis

Incidence and pathophysiology

In the general population of patients affected by IE, the incidence of right-sided structure involvement is very low (<5%).^{78,79} However, in patients with IVDA, the incidence of right-sided IE becomes preeminent and the most frequently affected valve is the tricuspid valve (58–80%).^{80–82}

Echocardiographic methods and findings

The relative proximity of the tricuspid valve to the ultrasound transducer and the young age (and consequent good thoracic

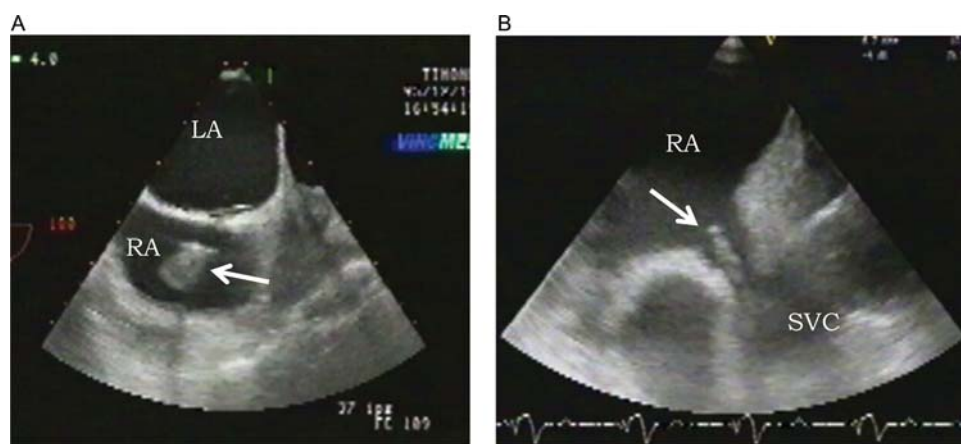


Figure 12 Pacemaker lead infective endocarditis (transoesophageal echocardiography). (A) Typical vegetation on a pacemaker lead (arrow). (B) Thickening of the pacemaker lead with a sleeve-like appearance (arrow). RA, right atrium; LA, left atrium; SVC, superior vena cava.

ultrasound windows) of many patients at risk for right-sided IE explain why this valve is often well imaged by TTE. Usually, the right ventricular inflow view and the subcostal views provide useful information. Careful selection of transducers (sometimes higher frequency transducers may be used to improve spatial resolution), the use of the 'zoom function', and paying attention to the adjustment of sector width, depth, and focus settings will help in accurate identification of vegetations.

The need for routine TEE in right-sided IE has been questioned.⁸³ However, TEE may be useful in detecting perivalvular abscess and unusual localizations of right-sided IE such as infection on the Eustachian valve^{84,85} or on the Chiari network. Transoesophageal echocardiography is also indicated in patients with poor image quality with TTE, in those who have negative TTE despite a moderate or high level of clinical suspicion of IE (especially in the setting of staphylococcal bacteraemia),⁸⁶ and when an associated left heart involvement is suspected. Vegetations on PM leads,⁷³ indwelling catheters, and right-sided prostheses are particularly difficult to diagnose with TTE because reverberations and artefacts produced by the intracardiac material may mask small vegetations attached to these structures. When there is a suspicion of right-sided IE in such patients, TEE is usually indicated.

The key echocardiographic finding in right-sided IE is a vegetation on the tricuspid or rarely the pulmonary valve (Figure 13). Similar to vegetations on the left-sided valves, they tend to be localized on the atrial side of the tricuspid valve and the ventricular side of the pulmonary valve in the path of the regurgitant jet. Tricuspid vegetations are often large and may exceed

2 cm (Figure 13, left upper panel). On rare occasions, vegetations may be sufficiently large to mimic an intracardiac tumour (Figure 13, right upper panel). Large vegetations (>2 cm) have been identified as an independent predictor of mortality together with fungal aetiology.^{78,87}

Entrapment of an embolized vegetation in the tricuspid chordal apparatus is sometimes seen, as well as mural vegetations in patients with congenital heart diseases and left-to-right shunts (Figure 13, lower panel). Similarly, embolized vegetations have been seen floating free in the right ventricle or pulmonary artery and pulmonary embolism in the setting of high-grade fever may be the first clinical sign of right-sided endocarditis.⁸⁸

Limitations and pitfalls in the diagnosis of right-sided infective endocarditis

Occasionally, the presence of normal anatomical variants such as Chiari network or prominent Eustachian valve may cause diagnostic confusion, more particularly with TTE. Similarly, venous catheters erroneously placed in the right atrium need to be identified and distinguished from vegetations. Right atrial thrombus may be distinguished from vegetation in that it is less likely to lie in the path of the jet and tends to layer on the right atrial wall. Past infection with damage to the tricuspid valve is commonly seen in this group, so the presence of vegetation does not in itself signify the presence of active infection. Extensive valve destruction and severe regurgitation are a common sequel of right-sided IE. Although older or healed vegetations tend to be more echogenic and may even be calcified, this finding cannot reliably

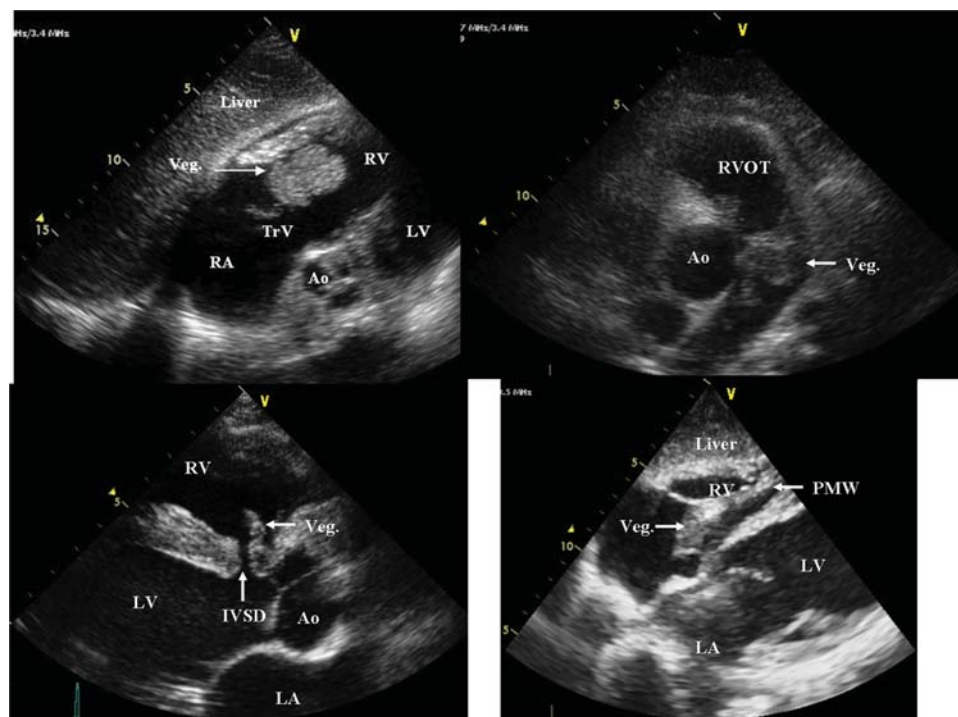


Figure 13 Cases of right-sided infective endocarditis (see text for details). AO, aorta; LV, left ventricle; LA, left atrium; RV, right ventricle; Veg, vegetation; PMW, pacemaker wire; IVSD, interventricular septal defect; TrV, tricuspid valve.

distinguish new from old infection. It should be underlined that echocardiographic findings always need to be taken in their clinical context.

Key points

Transthoracic echocardiography is of major value in the assessment of patients with right-sided IE.

Recommendations¹⁰

- 1. Transoesophageal echocardiography is not mandatory in isolated right-sided native valve IE with good-quality TTE examination and unequivocal echocardiographic findings.**
- 2. The size of the tricuspid vegetation and the severity of the tricuspid regurgitation must be evaluated by echocardiography, because these measurements have the potential to influence the therapeutic strategy.**

4. Negative blood culture infective endocarditis

Higher morbidity and mortality have been traditionally attributed to patients suffering endocarditis with negative blood cultures (NBCE).^{11,22,89} It has been proposed that delay in diagnosis and initiation of treatment while waiting to obtain positive results in blood cultures would be one of the most important reasons for this, especially before the advent of echocardiography.¹¹

Incidence of NBCE varies from 5 to more than 10% in most recent series.⁹⁰ The most common reason for obtaining negative blood cultures in IE is the administration of antibiotics prior to the collection of samples⁹¹ and non-bacterial organisms or fastidious slow-growing bacteria.

The routine use of echocardiography has overcome the potential limitations of delay in diagnosis with a clear impact in the prognosis of NBCE. Routine echocardiography allows an early diagnosis and oriented treatment approach and therefore overcomes in part the worse natural history of NBCE patients.^{92,93} The use of both TTE and TEE should be recommended in this setting.

Conclusion and future directions

Echocardiography plays a key role in IE, concerning its diagnosis, the diagnosis of its complications, its follow-up under therapy, and its prognostic assessment. Echocardiography is particularly useful for the initial assessment of embolic risk and in decision-making in IE. Transoesophageal echocardiography plays a major role both before surgery and during surgery (intraoperative echocardiography). Echocardiographic results must be taken into consideration for both the decision to operate patients or not and the choice of the optimal timing for surgery. Recent advances in three-dimensional imaging offer additional importance to the echocardiographic evaluation of patients with IE. In all cases, however, the results of echocardiographic studies may be interpreted taking into account the clinical features of the patient.

Conflict of interest: none declared.

References

- Habib G. Embolic risk in subacute bacterial endocarditis. Role of transesophageal echocardiography. *Curr Cardiol Rep* 2003;**5**:129–36.
- Hoen B, Alla F, Selton-Suty C, Beguinot I, Bouvet A, Briancon S et al. Changing profile of infective endocarditis: results of a 1-year survey in France. *J Am Med Assoc* 2002;**288**:75–81.
- Hasbun R, Vikram HR, Barakat LA, Buenconsejo J, Quagliarello VJ. Complicated left-sided native valve endocarditis in adults: risk classification for mortality. *J Am Med Assoc* 2003;**289**:1933–40.
- Tornos P, lung B, Permanyer-Miralda G, Baron G, Delahaye F, Gohlke-Barwolf C et al. Infective endocarditis in Europe: lessons from the Euro heart survey. *Heart* 2005;**91**:571–5.
- Habib G, Avierinos JF, Thuny F. Aortic valve endocarditis; is there an optimal surgical timing? *Curr Opin Cardiol* 2007;**22**:77–83.
- Horstkotte D, Follath F, Gutschik E, Lengyel M, Oto A, Pavie A et al. Guidelines on prevention, diagnosis and treatment of infective endocarditis executive summary; the task force on infective endocarditis of the European society of cardiology. *Eur Heart J* 2004;**25**:267–76.
- Baddour LM, Wilson WR, Bayer AS, Fowler VG Jr, Bolger AF, Levison ME et al. Infective endocarditis: diagnosis, antimicrobial therapy, and management of complications: a statement for healthcare professionals from the Committee on Rheumatic Fever, Endocarditis, and Kawasaki Disease, Council on Cardiovascular Disease in the Young, and the Councils on Clinical Cardiology, Stroke, and Cardiovascular Surgery and Anesthesia, American Heart Association: endorsed by the Infectious Diseases Society of America. *Circulation* 2005;**111**:e394–e434.
- Nishimura RA, Carabello BA, Faxon DP, Freed MD, Lytle BW, O’Gara PT et al. ACC/AHA 2008 guideline update on valvular heart disease: focused update on infective endocarditis. A report of the American College of Cardiology/American Heart Association Task Force on practice guidelines. *Circulation* 2008;**118**:887–96.
- Bonow RO, Carabello BA, Chatterjee K, de Leon AC Jr, Faxon DP, Freed MD et al. 2008 focused update incorporated into the ACC/AHA 2006 guidelines for the management of patients with valvular heart disease: a report of the American College of Cardiology/American Heart Association Task Force on Practice Guidelines (Writing Committee to revise the 1998 guidelines for the management of patients with valvular heart disease). Endorsed by the Society of Cardiovascular Anesthesiologists, Society for Cardiovascular Angiography and Interventions, and Society of Thoracic Surgeons. *J Am Coll Cardiol* 2008;**52**:e1–e142.
- Habib G, Hoen B, Tornos P, Thuny F, Prendergast B, Vilacosta I et al.; ESC Committee for Practice Guidelines (CPG). Guidelines on the prevention, diagnosis, and treatment of infective endocarditis (new version 2009): The Task Force on the Prevention, Diagnosis, and Treatment of Infective Endocarditis of the European Society of Cardiology (ESC). *Eur Heart J* 2009;**30**:2369–413.
- Durack DT, Lukes AS, Bright DK. New criteria for diagnosis of infective endocarditis: utilization of specific echocardiographic findings. Duke Endocarditis Service. *Am J Med* 1994;**96**:200–9.
- Evangelista A, Gonzalez-Alujas MT. Echocardiography in infective endocarditis. *Heart* 2004;**90**:614–7.
- Karalis DG, Bansal RC, Hauck AJ, Ross JJ Jr, Applegate PM, Jutzy KR et al. Transesophageal echocardiographic recognition of subaortic complications in aortic valve endocarditis. Clinical and surgical implications. *Circulation* 1992;**86**:353–62.
- Daniel WG, Mügge A, Martin RP et al. Improvement in the diagnosis of abscesses associated with endocarditis by transesophageal echocardiography. *N Engl J Med* 1991;**324**:795–800.
- Vilacosta I, San Roman JA, Sarria C, Iturralde E, Graupner C, Batlle E et al. Clinical, anatomic, and echocardiographic characteristics of aneurysms of the mitral valve. *Am J Cardiol* 1999;**84**:110–3, A119.
- Habib G. Management of infective endocarditis. *Heart* 2006;**92**:124–30.
- Habib G, Derumeaux G, Avierinos JF, Casalta JP, Jamal F, Volot F, Garcia M et al. Value and limitations of the Duke criteria for the diagnosis of infective endocarditis. *J Am Coll Cardiol* 1999;**33**:2023–9.
- Sochowski RA, Chan KL. Implication of negative results on a monoplane transeophageal echocardiographic study in patients with suspected infective endocarditis. *J Am Coll Cardiol* 1993;**21**:216–21.
- Vieira ML, Grinberg M, Pomerantzeff PM, Andrade JL, Mansur AJ. Repeated echocardiographic examinations of patients with suspected infective endocarditis. *Heart* 2004;**90**:1020–4.
- Hill EE, Herijgers P, Claus P, Vanderschueren S, Peetermans WE, Herregods MC. Abscess in infective endocarditis: the value of transesophageal echocardiography and outcome: a 5-year study. *Am Heart J* 2007;**154**:923–8.
- Liu YW, Tsai WC, Lin CC, Hsu CH, Li WT, Lin LJ et al. Usefulness of real-time three-dimensional echocardiography for diagnosis of infective endocarditis. *Scand Cardiovasc J* 2009;**43**:318–23.

22. Bayer A, Bolger A, Taubert K, Wilson W, Steckelberg J, Karchmer A et al. Diagnosis and management of infective endocarditis and its complications. *Circulation* 1998;**98**:2936–48.
23. Nadjji G, Rusinaru D, Rémy JP, Jéu A, Sorel C, Tribouilloy C. Heart failure in left-sided native valve infective endocarditis: characteristics, prognosis, and results of surgical treatment. *Eur J Heart Fail* 2009;**11**:668–75.
24. Stout KK, Verrier ED. Acute valvular heart disease: changing concepts in disease management. *Circulation* 2009;**119**:3232–41.
25. De Castro S, d'Amati G, Cartoni D, Venditti M, Magni G, Gallo P et al. Valvular perforation in left-sided infective endocarditis: a prospective echocardiographic evaluation and clinical outcome. *Am Heart J* 1997;**134**:656–64.
26. Vilacosta I, San Roman JA, Sarria C, Iturralde E, Graupner C, Batlle E et al. Clinical, anatomic, and echocardiographic characteristics of aneurysms of mitral valve. *Am J Cardiol* 1999;**84**:110–3, A11.
27. Oh J, Hatle L, Sinak L, Seward J, Tajik AJ. Characteristic Doppler echocardiographic pattern of mitral inflow velocity in severe aortic regurgitation. *J Am Coll Cardiol* 1989;**14**:1712–7.
28. Eusebio J, Louie EK, Edwards LC III, Loeb HS, Scanlon PJ. Alterations in transmitral flow dynamics in patients with early mitral valve closure and aortic regurgitation. *Am Heart J* 1994;**128**:941–7.
29. Piper C, Hetzer R, Korfer R, Bergemann R, Horstkotte D. The importance of secondary mitral valve involvement in primary aortic valve endocarditis: the mitral kissing vegetation. *Eur Heart J* 2002;**23**:79–86.
30. Chan KL. Early clinical course and long-term outcome of patients with infective endocarditis complicated by perivalvular abscess. *CMAJ* 2002;**167**:19–24.
31. Anguera I, Miro JM, Vilacosta I, Almirante B, Anguita M, Munoz P et al. Aorto-cavitary fistulous tract formation in infective endocarditis: clinical and echocardiographic features of 76 cases and risk factors for mortality. *Eur Heart J* 2005;**26**:288–97.
32. Tingleff J, Egeblad H, Gotsche CO, Baandrup U, Kristensen BO, Pilegaard H et al. Perivalvular cavities in endocarditis: abscesses versus pseudoaneurysms? A transoesophageal Doppler echocardiographic study in 118 patients with endocarditis. *Am Heart J* 1995;**130**:93–100.
33. Jenkins NP, Habib G, Prendergast BD. Aorto-cavitary fistulae in infective endocarditis: understanding a rare complication through collaboration. *Eur Heart J* 2005;**26**:213–4.
34. Tribouilloy C, Ruiz V, Roudaut R, Eicher JC, Denis B, Lusson JR et al. Outcome of aortic valve ring abscesses after medical treatment: attempt to identify criteria of favorable prognosis. *Presse Med* 1996;**25**:1276–80.
35. Kunis RL, Sherrid MV, McCabe JB, Grieco MH, Dwyer EM Jr. Successful medical therapy of mitral annular abscess complicating infective endocarditis. *J Am Coll Cardiol* 1986;**7**:953–5.
36. Rohmann S, Erbel R, Darius H, Gorge G, Makowski T, Zotz R et al. Prediction of rapid versus prolonged healing of infective endocarditis by monitoring vegetation size. *J Am Soc Echocardiogr* 1991;**4**:465–74.
37. Di Salvo G, Habib G, Pergola V, Avierinos JF, Philip E, Casalta JP et al. Echocardiography predicts embolic events in infective endocarditis. *J Am Coll Cardiol* 2001;**37**:1069–76.
38. Steckelberg JM, Murphy JG, Ballard D, Bailey K, Tajik AJ, Taliencio CP et al. Emboli in infective endocarditis: the prognostic value of echocardiography. *Ann Intern Med* 1991;**114**:635–40.
39. De Castro S, Magni G, Beni S, Cartoni D, Fiorelli M, Venditti M et al. Role of transthoracic and transoesophageal echocardiography in predicting embolic events in patients with active infective endocarditis involving native cardiac valves. *Am J Cardiol* 1997;**80**:1030–4.
40. Thuny F, Di Salvo G, Belliard O, Avierinos JF, Pergola V, Rosenberg V et al. Risk of embolism and death in infective endocarditis: prognostic value of echocardiography: a prospective multicenter study. *Circulation* 2005;**112**:69–75.
41. Vilacosta I, Graupner C, San Roman JA, Sarria C, Ronderos R, Fernandez C et al. Risk of embolization after institution of antibiotic therapy for infective endocarditis. *J Am Coll Cardiol* 2002;**39**:1489–95.
42. Erbel R, Liu F, Ge J, Rohmann S, Kupferwasser I. Identification of high-risk subgroups in infective endocarditis and the role of echocardiography. *Eur Heart J* 1995;**16**:588–602.
43. Sanfilippo AJ, Picard MH, Newell JB, Rosas E, Davidoff R, Thomas JD et al. Echocardiographic assessment of patients with infectious endocarditis: prediction of risk for complication. *J Am Coll Cardiol* 1991;**18**:1191–9.
44. Mugge A, Daniel WG, Frank G, Lichtlen PR. Echocardiography in infective endocarditis: reassessment of prognostic implications of vegetation size determined by the transthoracic and the transoesophageal approach. *J Am Coll Cardiol* 1989;**14**:631–8.
45. Dickerman SA, Abrutyn E, Barsic B, Bouza E, Cecchi E, Moreno A et al. The relationship between the initiation of antimicrobial therapy and the incidence of stroke in infective endocarditis: an analysis from the ICE Prospective Cohort Study (ICE-PCS). *Am Heart J* 2007;**154**:1086–94.
46. Cabell CH, Pond KK, Peterson GE, Durack DT, Corey GR, Anderson DJ et al. The risk of stroke and death in patients with aortic and mitral valve endocarditis. *Am Heart J* 2001;**142**:75–80.
47. Mylonakis E, Calderwood SB. Infective endocarditis in adults. *N Engl J Med* 2001;**345**:1318–30.
48. Hecht SR, Berger M. Right-sided endocarditis in intravenous drug users: prognostic features in 102 episodes. *Ann Intern Med* 1992;**117**:560–6.
49. Heiro M, Helenius H, Mäkilä S, Hohenthal U, Savunen T, Engblom E et al. Infective endocarditis in a Finnish teaching hospital: a study on 326 episodes treated during 1980–2004. *Heart* 2006;**92**:1457–62.
50. San Román JA, López J, Vilacosta I, Luaces M, Sarriá C, Revilla A et al. Prognostic stratification of patients with left-sided endocarditis determined at admission. *Am J Med* 2007;**120**:369.e1–7.
51. Wallace SM, Walton BI, Kharbanda RK, Hardy R, Wilson AP, Swanton RH. Mortality from infective endocarditis: clinical predictors of outcome. *Heart* 2002;**88**:53–60.
52. Vikram HR, Buenconsejo J, Hasbun R, Quagliarello VJ. Impact of valve surgery on 6-month mortality in adults with complicated, left-sided native valve endocarditis. A propensity analysis. *J Am Med Assoc* 2003;**290**:3207–14.
53. Hill EE, Herijgers P, Claus P, Vanderschueren S, Herregods MC, Peetermans WE. Infective endocarditis: changing epidemiology and predictors of 6-month mortality: a prospective cohort study. *Eur Heart J* 2007;**28**:196–203.
54. Martínez-Sellés M, Muñoz P, Estevez A, Del Castillo R, García-Fernández MA, Rodríguez-Crèixems M et al. Long-term outcome of infective endocarditis in non-intravenous drug users. *Mayo Clin Proc* 2008;**83**:1213–7.
55. Heiro M, Helenius H, Hurme S, Savunen T, Metsärinne K, Engblom E et al. Long-term outcome of infective endocarditis: a study on patients surviving over one year after the initial episode treated in a Finnish teaching hospital during 25 years. *BMC Infect Dis* 2008;**8**:49.
56. Shapira Y, Weisenberg DE, Vaturi M, Sharoni E, Raanani E, Sahar G et al. The impact of intraoperative echocardiography in infective endocarditis. *IMAJ* 2007;**9**:299–302.
57. Jung B, Rousseau-Pazaud J, Cormier B, Garbaz E, Fondard O, Brochet E et al. Contemporary results of mitral valve repair for infective endocarditis. *J Am Coll Cardiol* 2004;**43**:386–92.
58. Shapira Y, Vaturi M, Weisenberg DE, Raanani E, Sahar G, Snir E et al. Impact of intraoperative transoesophageal echocardiography in patients undergoing valve replacement. *Ann Thorac Surg* 2004;**78**:579–83.
59. Vongpatanasin W, Hillis LD, Lange RA. Prosthetic heart valves. *N Engl J Med* 1996;**335**:407–16.
60. Habib G, Thuny F, Avierinos JF. Prosthetic valve endocarditis: current approach and therapeutic options. *Prog Cardiovasc Dis* 2008;**50**:274–81.
61. Piper C, Korfer R, Horstkotte D. Prosthetic valve endocarditis. *Heart* 2001;**85**:590–93.
62. Mahesh B, Angelini G, Caputo M, Jin XY, Bryan A. Prosthetic valve endocarditis. *Ann Thorac Surg* 2005;**80**:1151–8.
63. Habib G, Tribouilloy C, Thuny F, Giorgi R, Brahim A, Amazouz M et al. Prosthetic valve endocarditis: who needs surgery? A multicentre study of 104 cases. *Heart* 2005;**91**:954–9.
64. Lopez J, Revilla A, Vilacosta I, Villacorta E, Gonzalez-Juanatey C, Gomez I et al. Definition, clinical profile, microbiological spectrum, and prognostic factors of early-onset prosthetic valve endocarditis. *Eur Heart J* 2007;**28**:760–5.
65. Pedersen WR, Walker M, Olson JD, Gobel F, Lange HW, Daniel JA et al. Value of transoesophageal echocardiography as an adjunct to transthoracic echocardiography in evaluation of native and prosthetic valve endocarditis. *Chest* 1991;**100**:351–6.
66. Lamas CC, Eykyn SJ. Suggested modifications to the Duke criteria for the clinical diagnosis of native valve and prosthetic valve endocarditis: analysis of 118 pathologically proven cases. *Clin Infect Dis* 1997;**25**:713–9.
67. Perez-Vazquez A, Farinas MC, Garcia-Palomo JD, Bernal JM, Revuelta JM, Gonzalez-Macias J. Evaluation of the Duke criteria in 93 episodes of prosthetic valve endocarditis: could sensitivity be improved? *Arch Intern Med* 2000;**160**:1185–91.
68. Uslan DZ, Sohail MR, St Sauver JL, Friedman PA, Hayes DL, Stoner SM et al. Permanent pacemaker and implantable cardioverter defibrillator infection. *Arch Intern Med* 2007;**167**:669–75.
69. Sohail MR, Uslan DZ, Khan AH, Friedman PA, Hayes DL, Wilson WR et al. Management and outcome of permanent pacemaker and implantable cardioverter-defibrillator infections. *J Am Coll Cardiol* 2007;**49**:1851–9.
70. Sohail MR, Uslan DZ, Khan AH, Friedman PA, Hayes DL, Wilson WR et al. Infective endocarditis complicating permanent pacemaker and implantable cardioverter-defibrillator infection. *Mayo Clin Proc* 2008;**83**:46–53.
71. Da Costa A, Lelievre H, Kirkorian G, Celard M, Chevalier P, Vandenesch F et al. Role of the preaxillary flora in pacemaker infections: a prospective study. *Circulation* 1998;**97**:1791–5.

72. Klug D, Lacroix D, Savoye C, Goullard L, Grandmougin D, Hennequin JL *et al*. Systemic infection related to endocarditis on pacemaker leads: clinical presentation and management. *Circulation* 1997;**95**:2098–107.
73. Vilacosta I, Sarriá C, San Román JA, Jiménez J, Castillo JA, Iturralde E *et al*. Usefulness of transesophageal echocardiography for diagnosis of infected transvenous permanent pacemakers. *Circulation* 1994;**89**:2684–7.
74. Victor F, De Place C, Camus C, Le Breton H, Leclercq C, Pavin D *et al*. Pacemaker lead infection: echocardiographic features, management, and outcome. *Heart* 1999;**81**:82–7.
75. Massoure P-L, Reuter S, Lafitte S, Laborderie J, Bordachard P, Clementy J *et al*. Pacemaker endocarditis: clinical features and management of 60 consecutive cases. *Pacing Clin Electrophysiol* 2007;**30**:12–9.
76. Dalal A, Asirvatham SJ, Chandrasekaran K, Seward JB, Tajik AJ. Intracardiac echocardiography in the detection of pacemaker lead endocarditis. *J Am Soc Echocardiogr* 2002;**15**:1027–8.
77. Ruttman E, Hangler HB, Kilo J, Hofer D, Muller LC, Hintringer F *et al*. Transvenous pacemaker lead removal is safe and effective even in large vegetations: an analysis of 53 cases of pacemaker lead endocarditis. *Pacing Clin Electrophysiol* 2006;**29**:231–6.
78. Scudeller L, Badano LP, Crapis M, Pagotto A, Viale PL. Population-based surveillance of infectious endocarditis in an Italian region. *Arch Intern Med* 2009;**169**:1720–3.
79. Revilla A, Lopez J, Villacorta E, Gómez I, Sevilla T, del Pozo MA *et al*. Isolated right-sided valvular endocarditis in non-intravenous drug users. *Rev Esp Cardiol* 2008;**61**:1253–9.
80. Mathew J, Addai T, Anand A, Morrobel A, Maheshwari P, Freels S. Clinical features site of involvement bacteriological findings outcome of infective endocarditis in intravenous drug abusers. *Arch Intern Med* 1995;**155**:1641–8.
81. Miro JM, Del Rio A, Mestres CA. Infective endocarditis in intravenous drug abusers and HIV-1 infected patients. *Infect Dis Clin North Am* 2002;**16**:273. iii.
82. Hubbell G, Cheitlin MD, Rapaport P. Presentation, management, follow-up evolution of infective endocarditis in drug addicts. *Am Heart J* 1981;**102**:85–94.
83. San Roman JA, Vilacosta I, Zamorano J, Almeria C, Sanchez-Harguindey L. Transesophageal echocardiography in right-sided endocarditis. *J Am Coll Cardiol* 1993;**21**:1226–30.
84. Sawhney N, Palakodeti V, Raisinghani A, Rickman LS, De Maria AN, Blanchard DG. Eustachian valve endocarditis: a case series and analysis of literature. *J Am Soc Echocardiogr* 2001;**14**:1139–42.
85. San Roman JA, Vilacosta I, Sarria C, Garcimartin I, Rollan MJ, Fernandez-Aviles E. Eustachian valve endocarditis: is it worth searching for? *Am Heart J* 2001;**142**:1037–40.
86. Moss R, Munt B. Injection drug use and right sided endocarditis. *Heart* 2003;**89**:577–81.
87. Martin-Davila P, Navas E, Fortun J, Moya JL, Cobo J, Pintado V *et al*. Analysis of mortality and risk factors associated with native valve endocarditis in drug users: the importance of vegetation size. *Am Heart J* 2005;**150**:1099–106.
88. Nucifora G, Badano LP, Hysko F, Allocca G, Gianfagna P, Fioretti PM. Pulmonary embolism and fever, when should right-sided infective endocarditis be considered? *Circulation* 2007;**115**:e173–6.
89. Zamorano J, de Isla LP, Malangatana G, Almeria C, Rodrigo JL, Aubele A *et al*. Infective endocarditis: mid-term prognosis in patients with good in-hospital outcome. *J Heart Valve Dis* 2005;**14**:303–9.
90. Tunkel AR, Kaye D. Endocarditis with negative blood cultures. *N Engl J Med* 1992;**326**:1215–7.
91. Hoen B, Selton-Suty C, Lacassin F, Etienne J, Briancon S, Leport C *et al*. Infective endocarditis in patients with negative blood cultures: analysis of 88 cases from one-year nationwide survey in France. *Clin Infect Dis* 1995;**20**:501–6.
92. Zamorano J, de Isla LP, Moura L, Almeria C, Rodrigo JL, Aubele A *et al*. Impact of echocardiography in the short- and long-term prognosis of patients with infective endocarditis and negative blood cultures. *J Heart Valve Dis* 2004;**13**:997–1004.
93. Zamorano J, Sanz J, Almeria C, Rodrigo JL, Samedí M, Herrera D *et al*. Differences between endocarditis with true negative blood cultures and those with previous antibiotic treatment. *J Heart Valve Dis* 2003;**12**:256–260.