

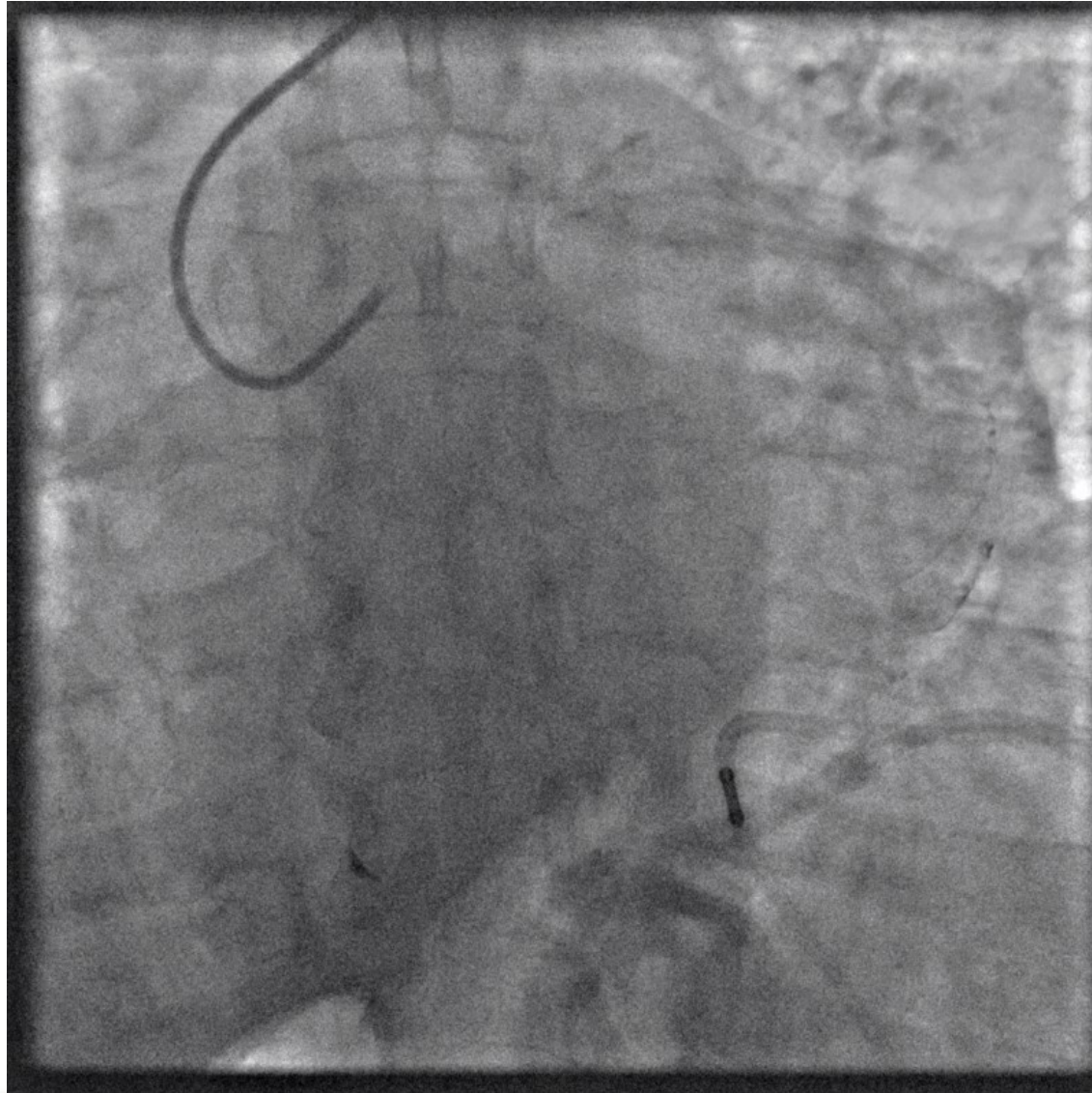My experience with the BRS. Case based presentation

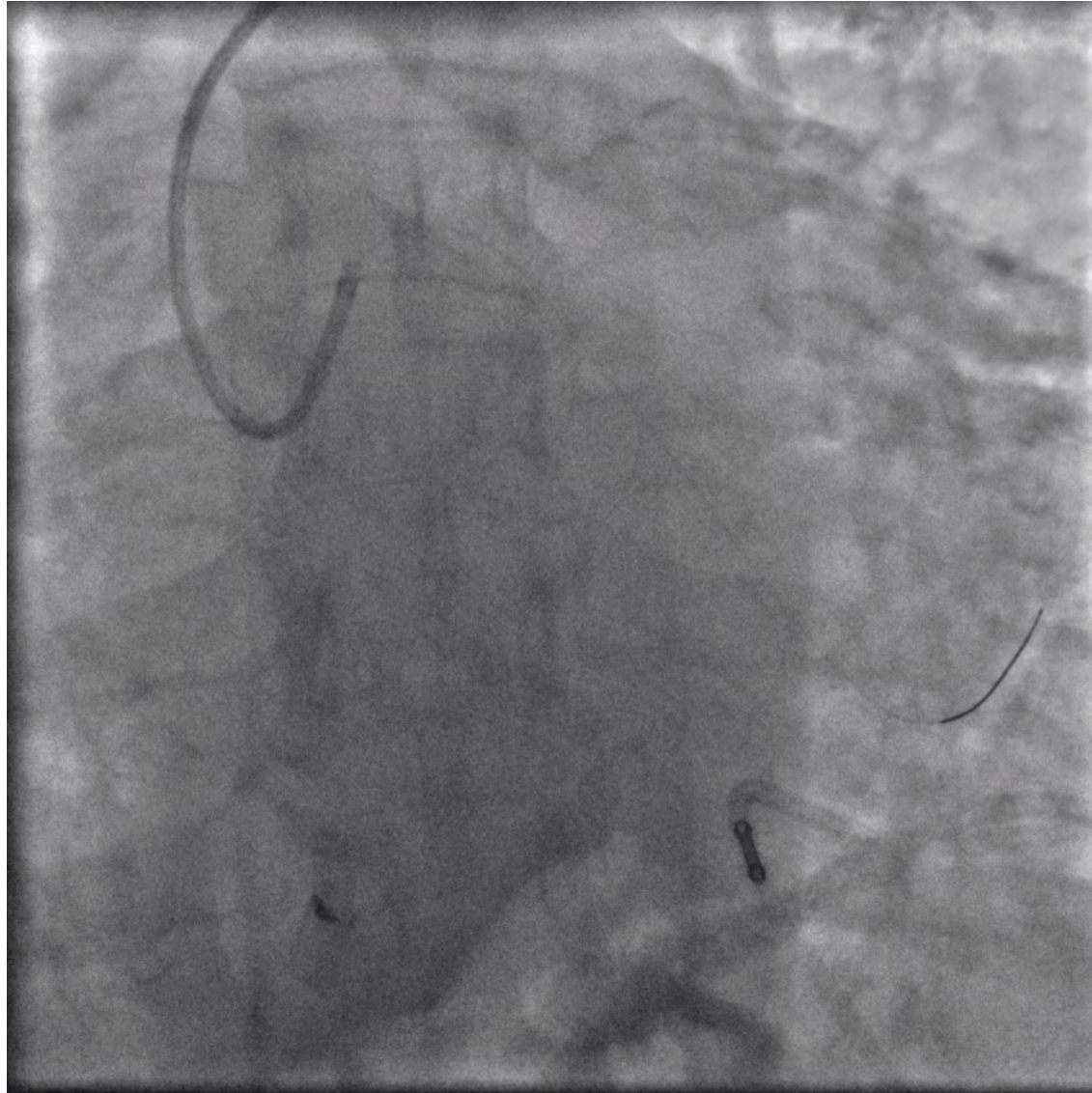Y.Louvard, ICPS, Massy, Générale de
santé, Ramsay, France

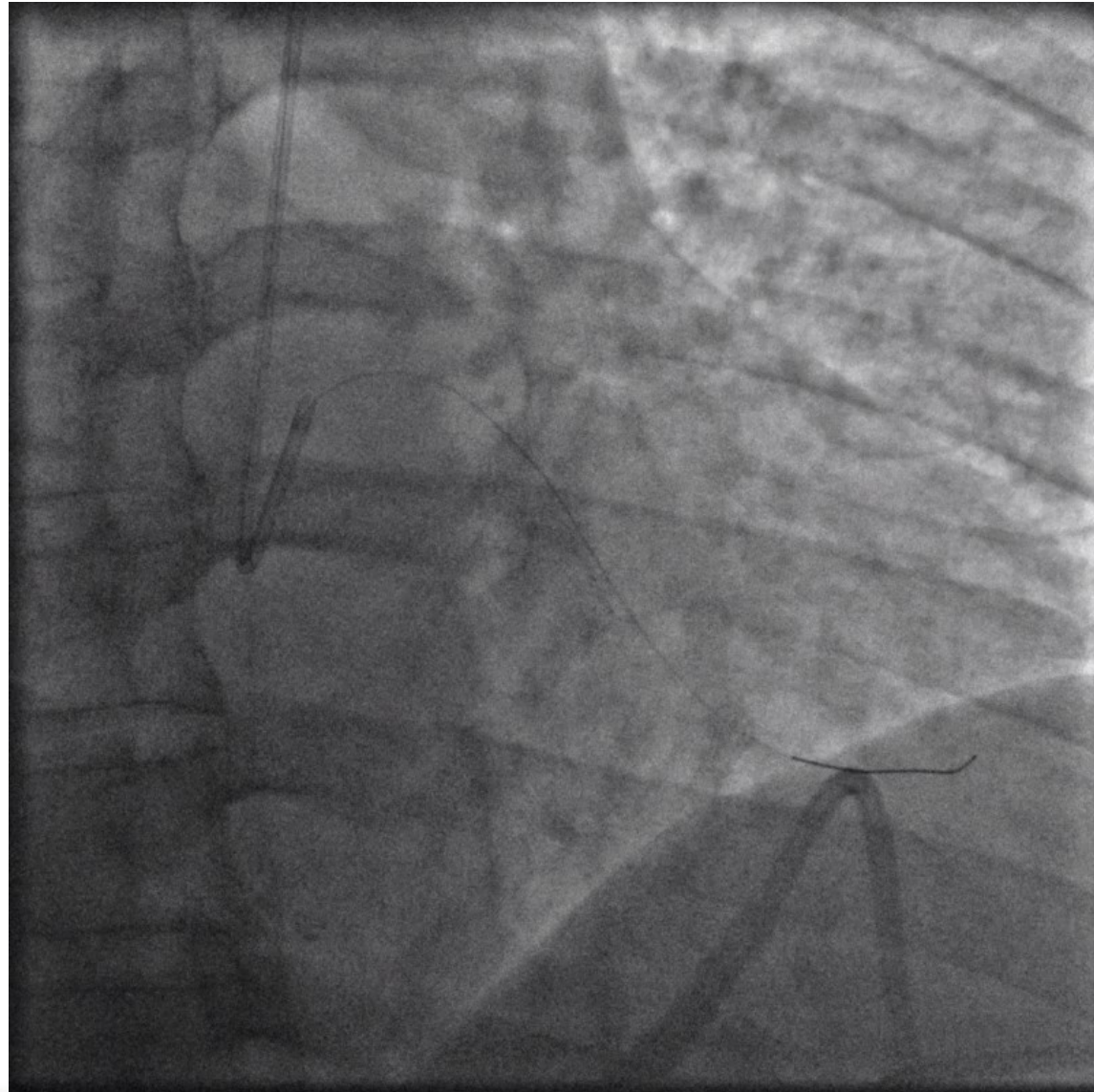
Bulgarian Bifurcation and Complex Coronary Interventions Course
22-23 January 2016
Tokuda Hospital, Sofia

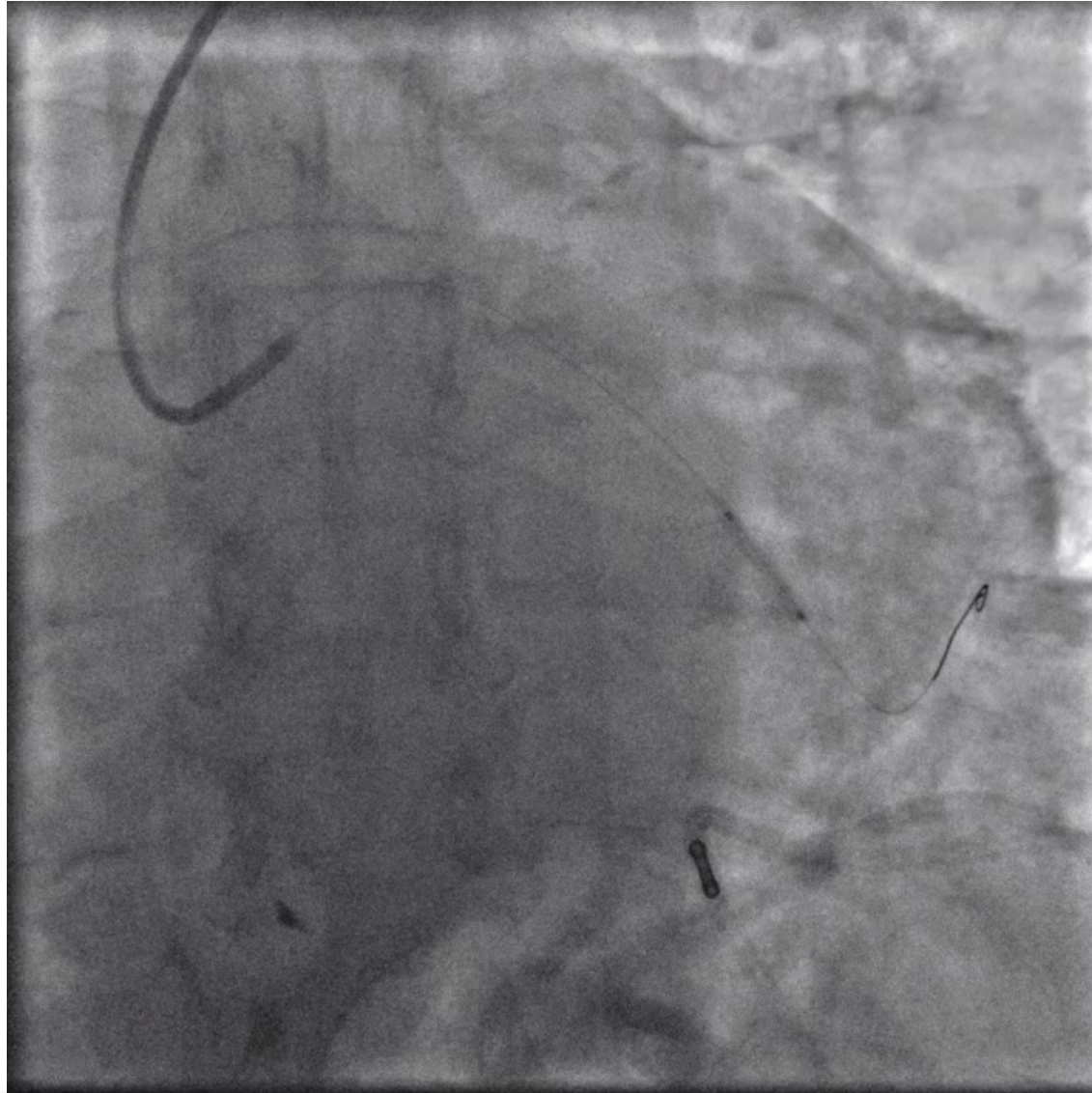2 VD, Absorb Compare (randomized)

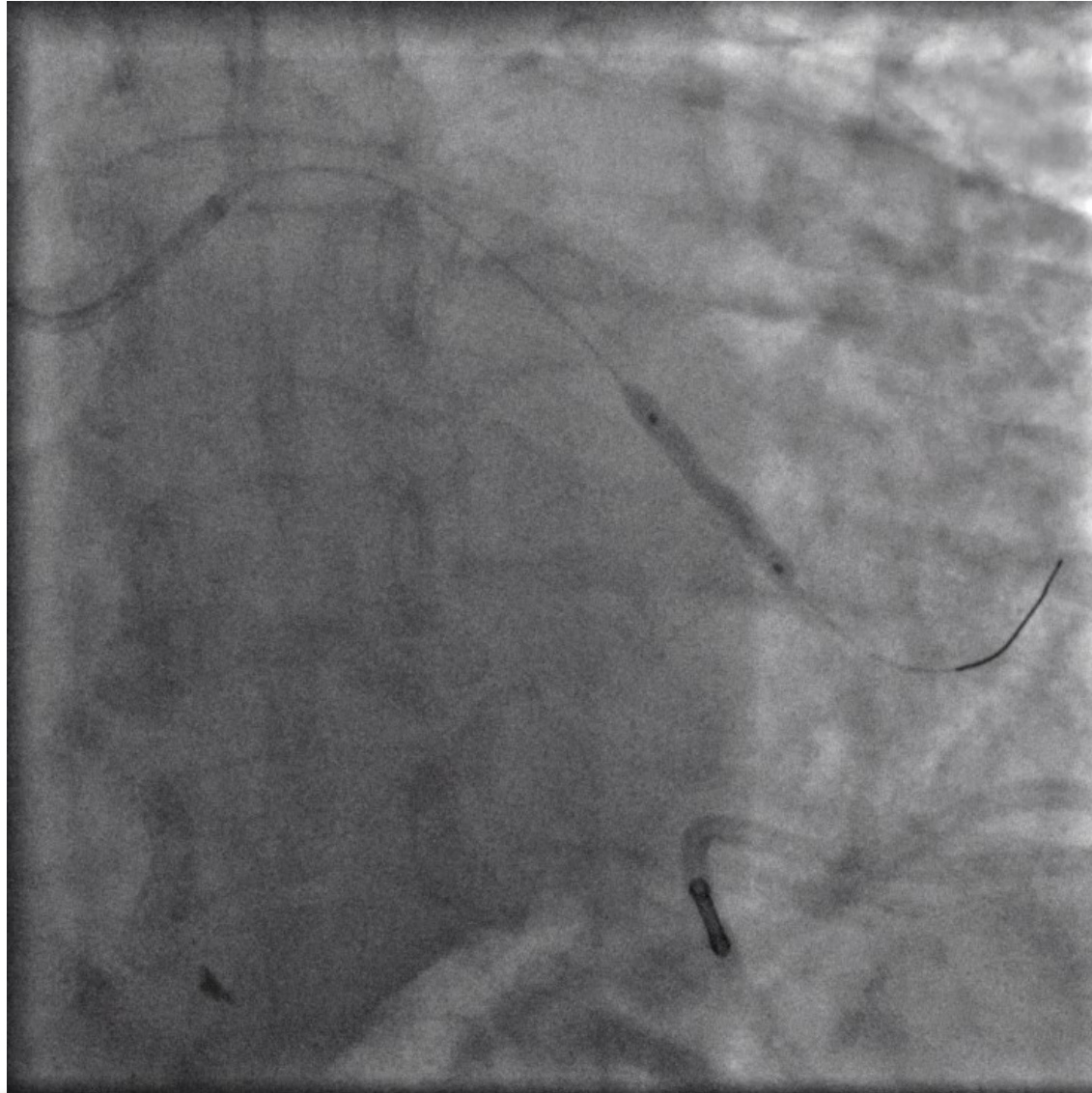
- Male
- 57 yo
- 99 kg 174 cms
- Stable angina
- Diabetes type2

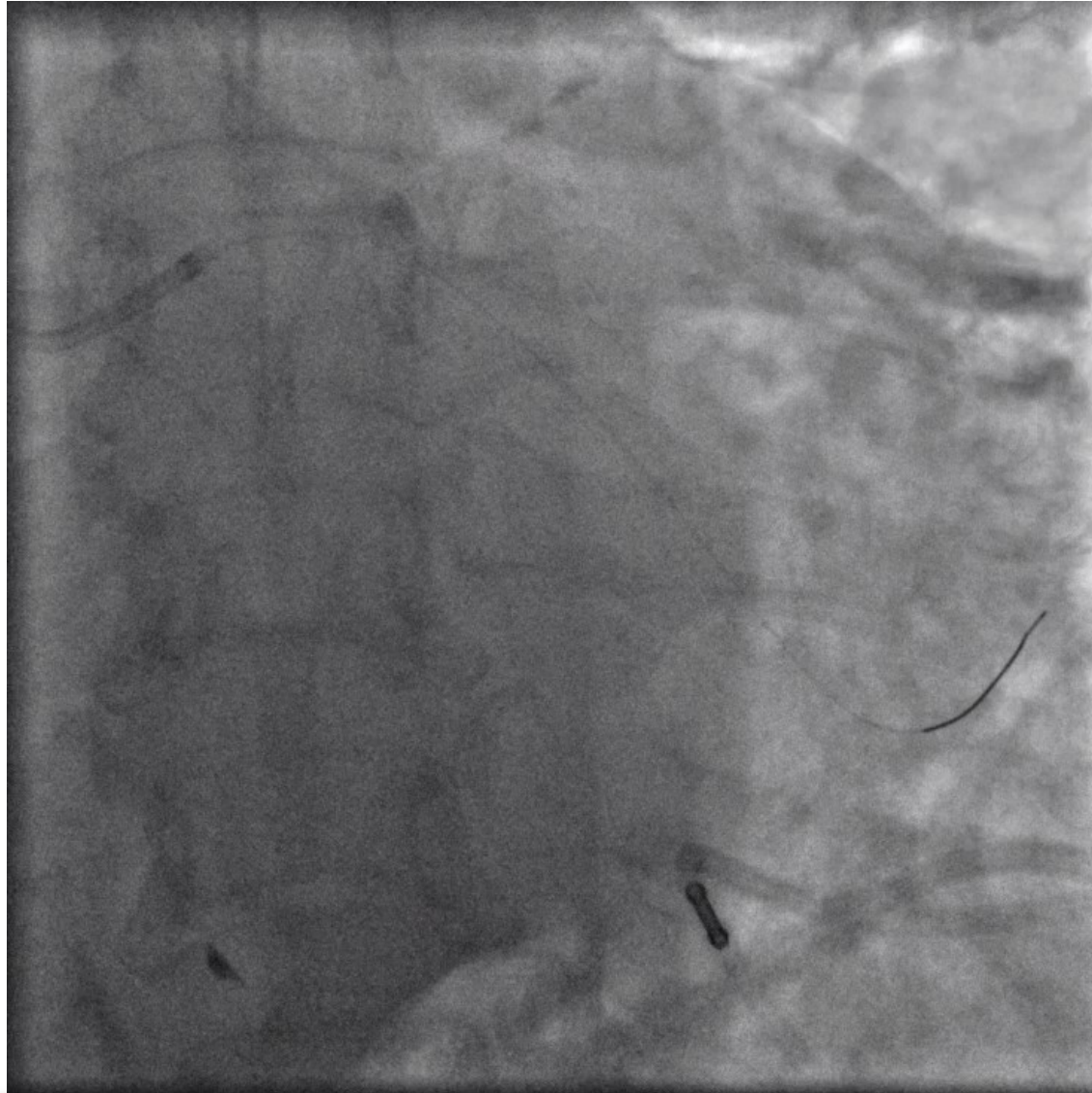


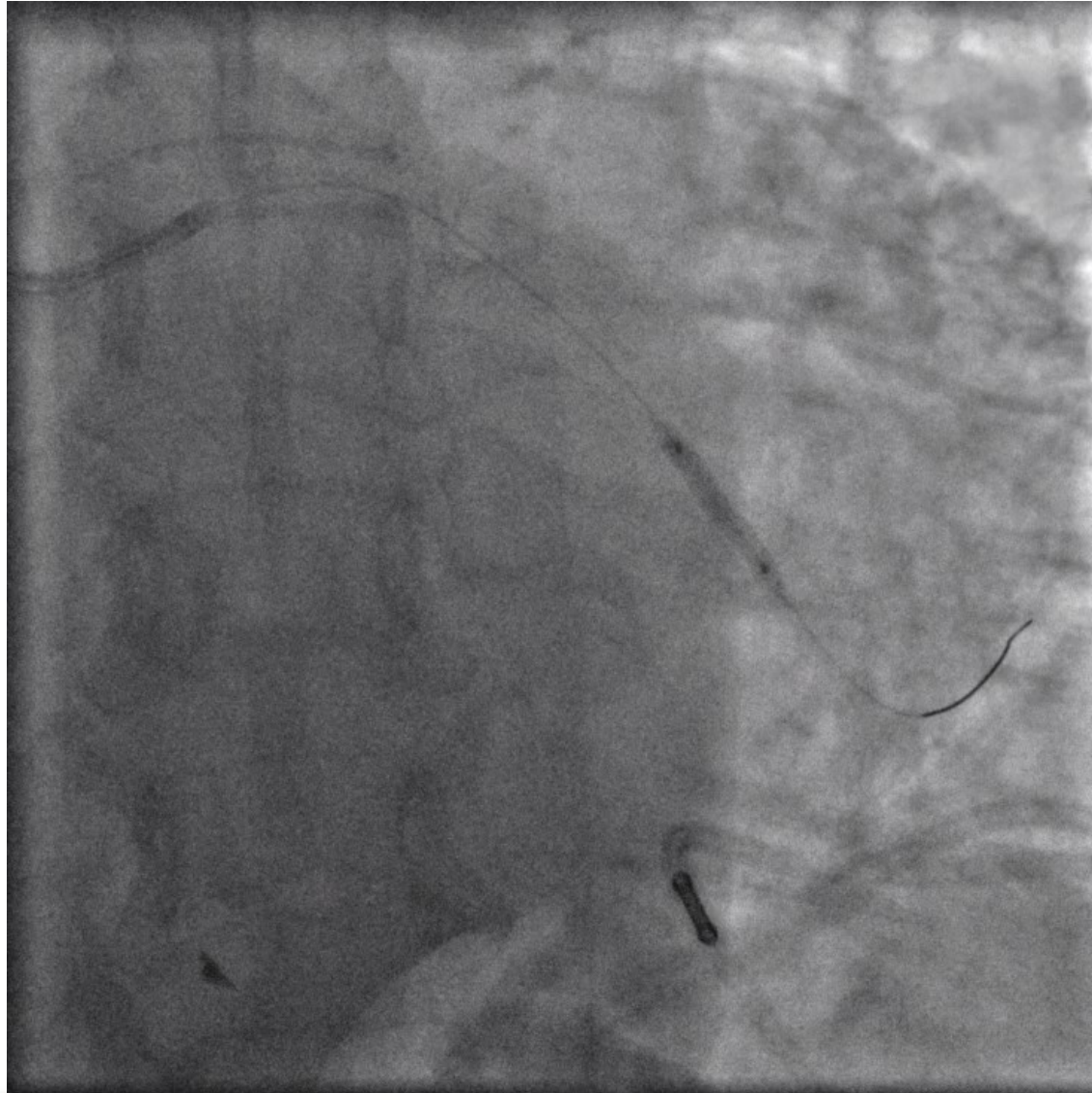
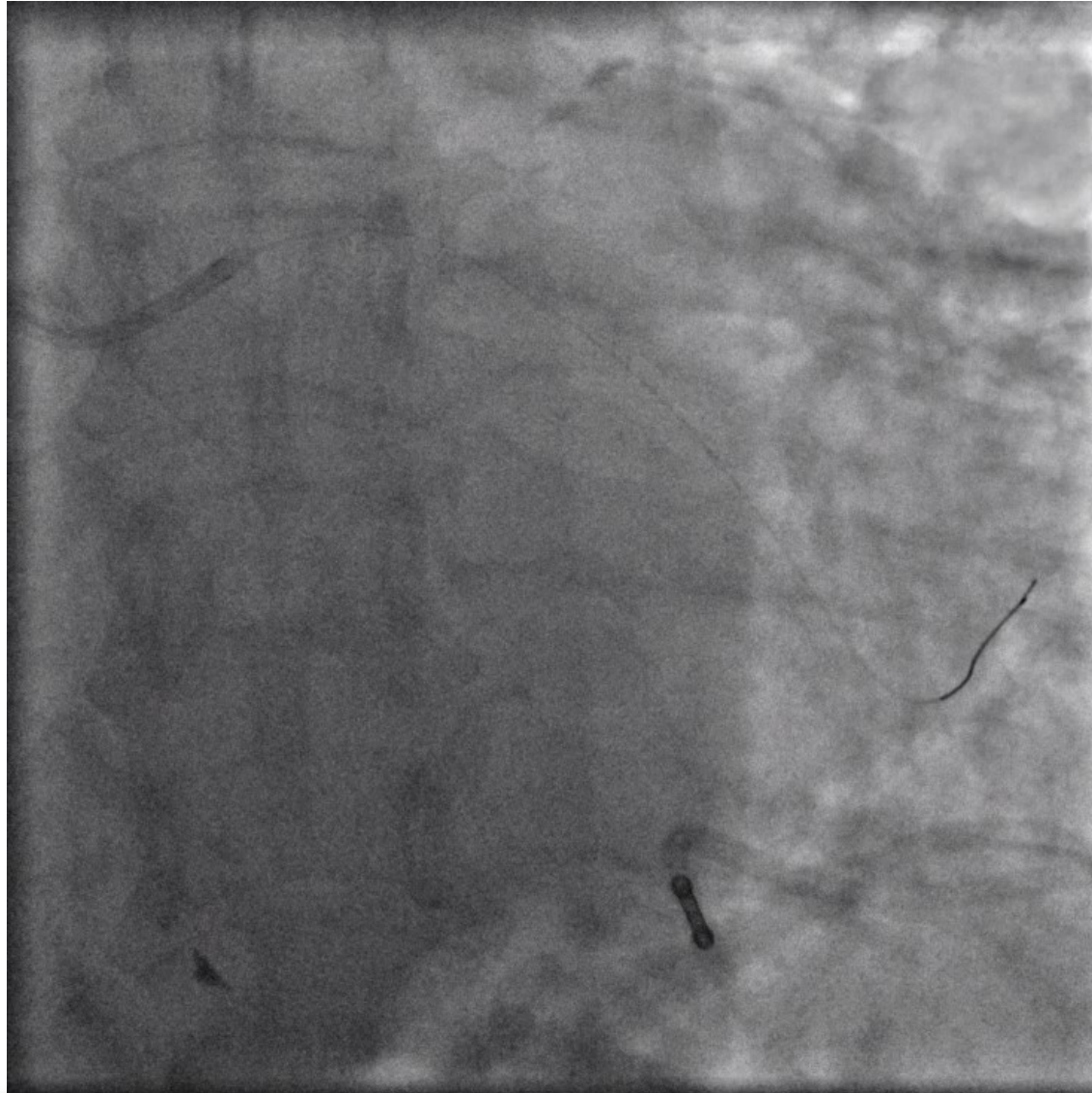


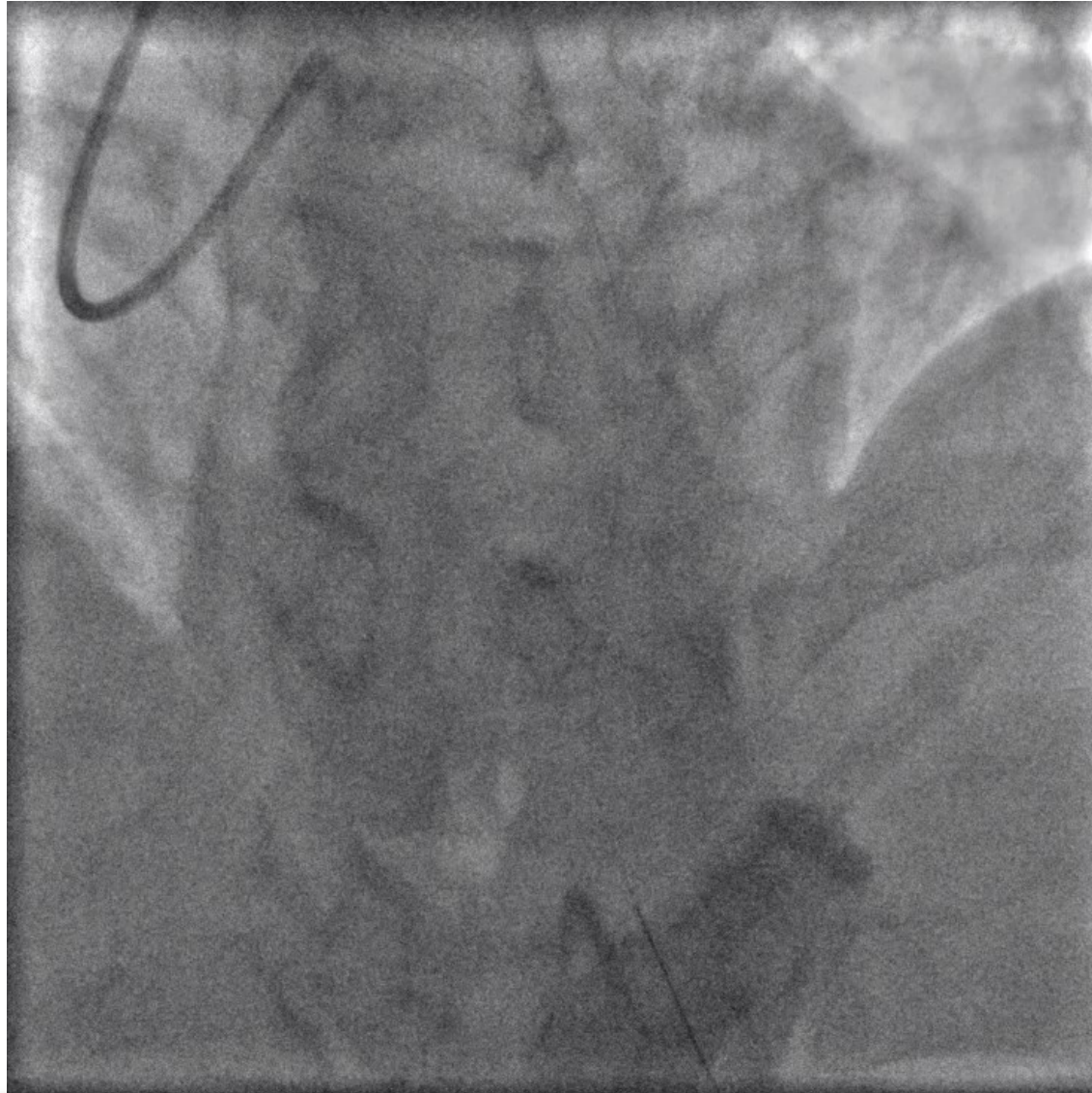


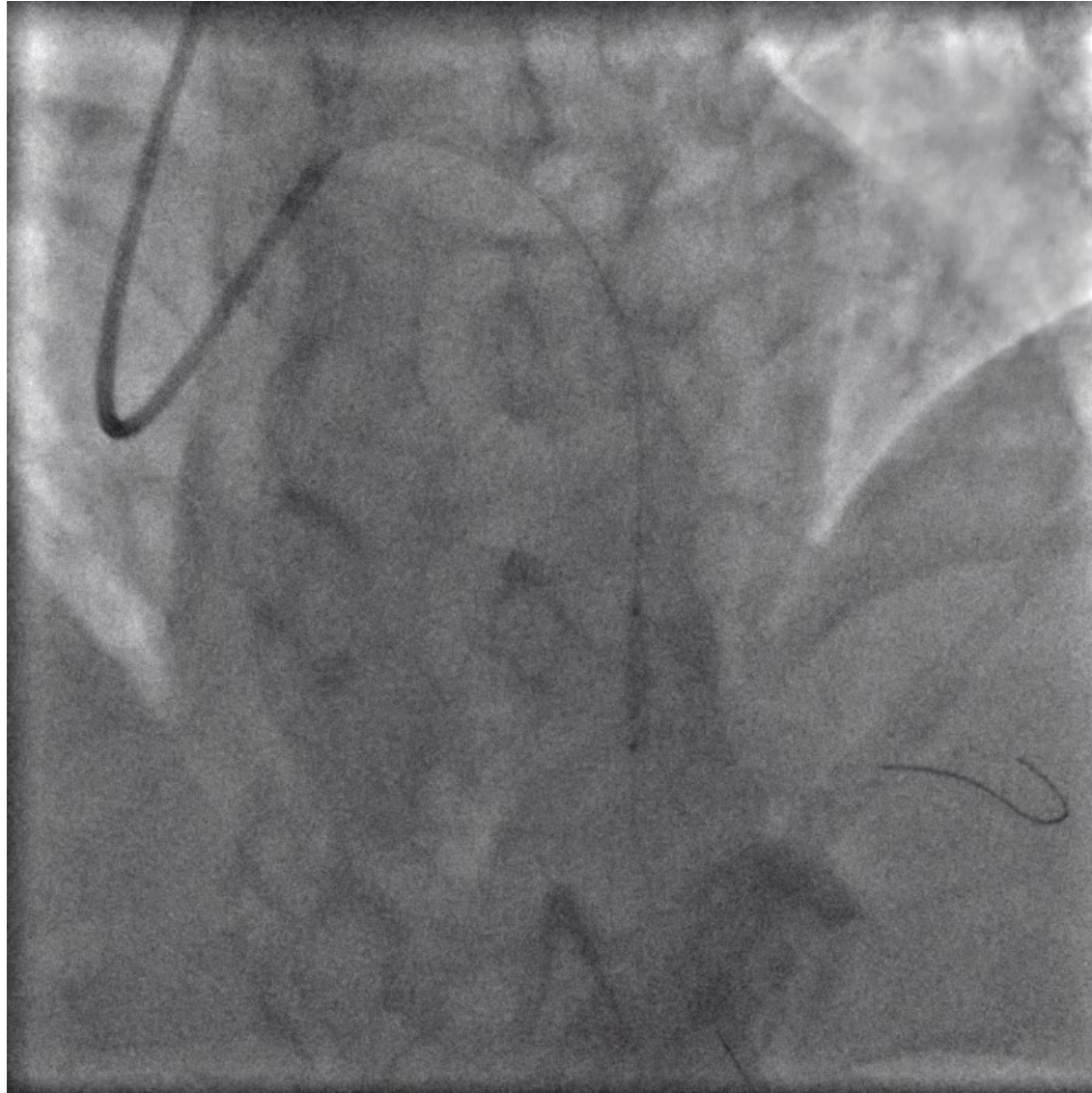




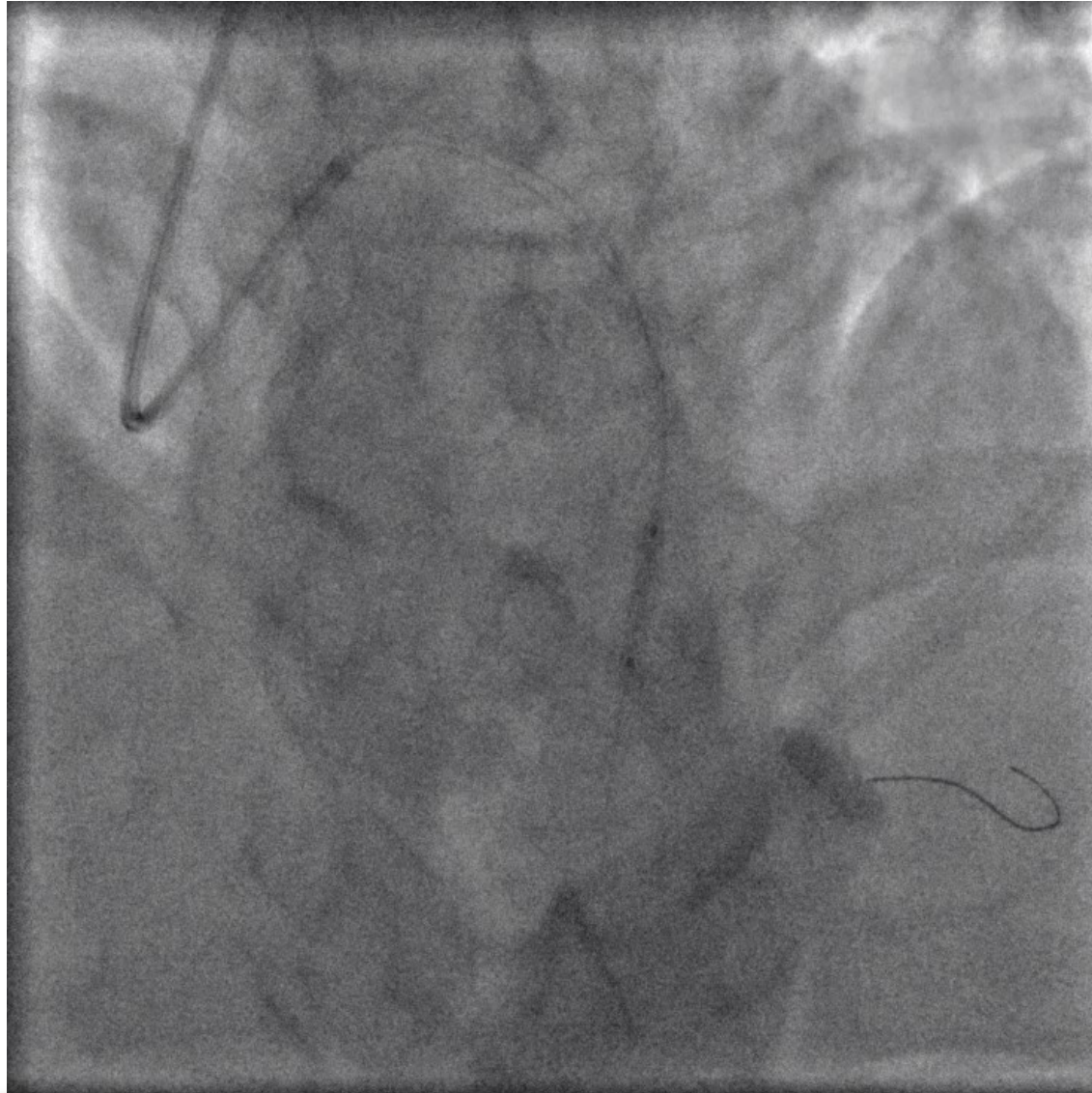

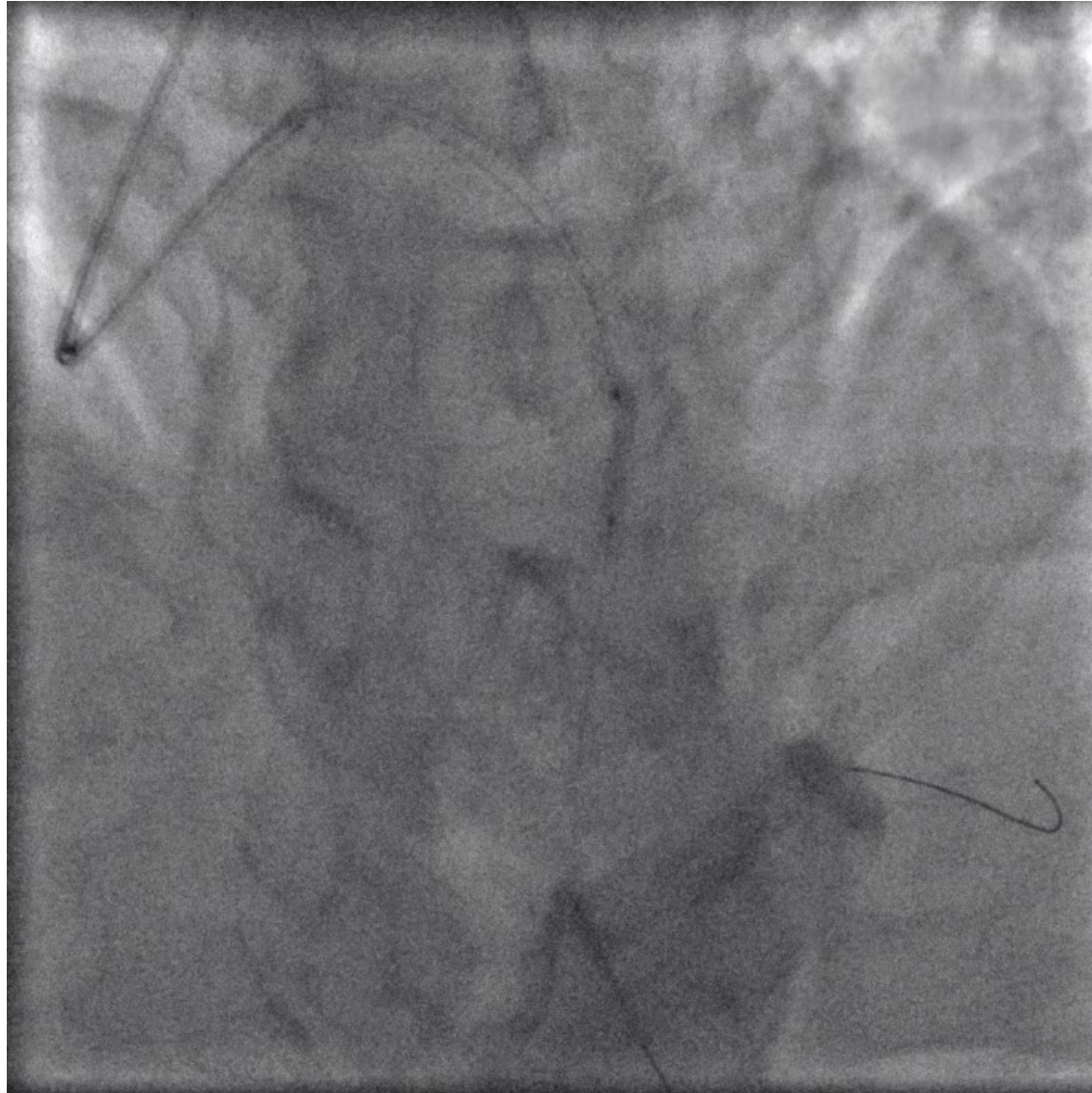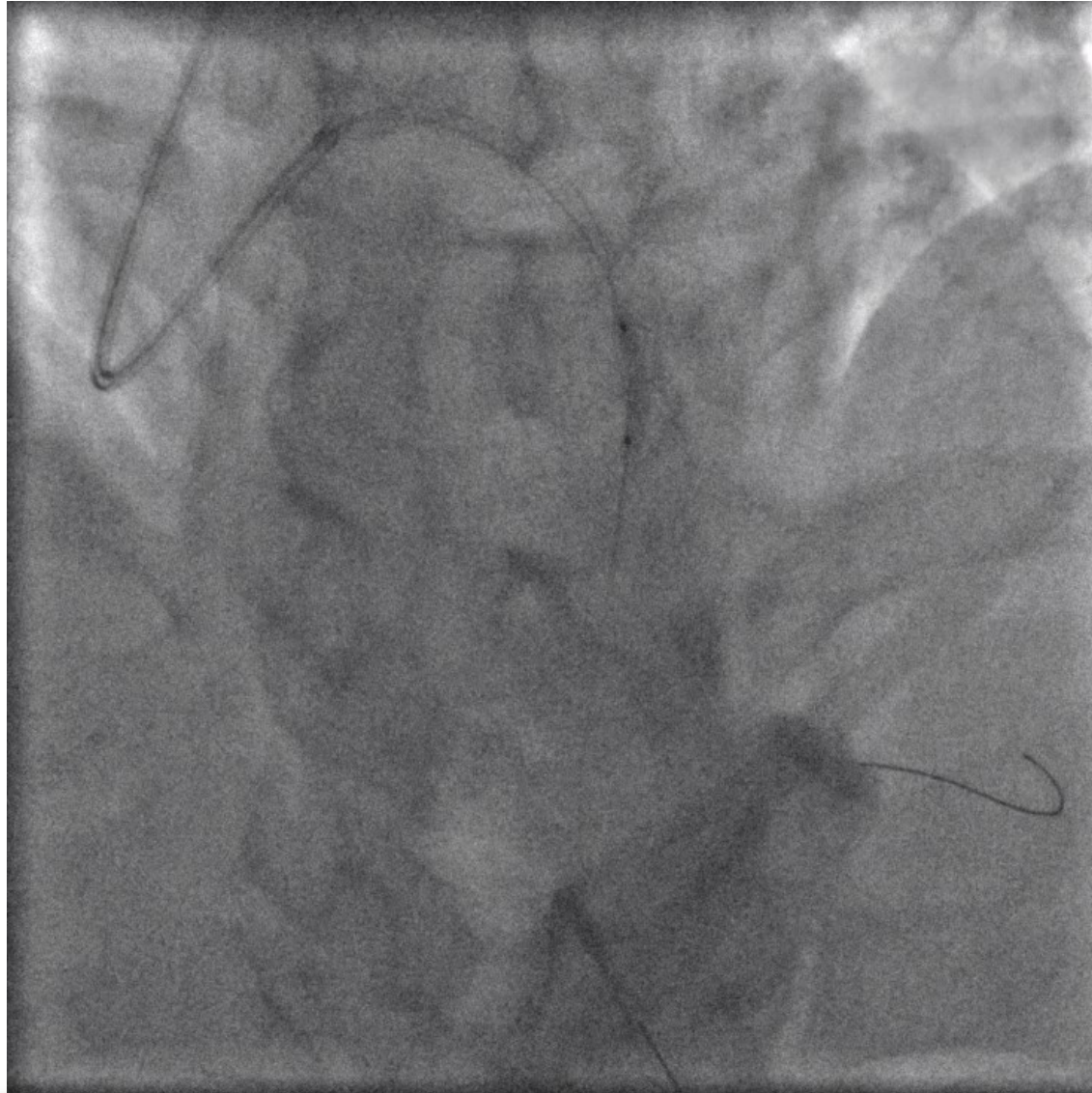


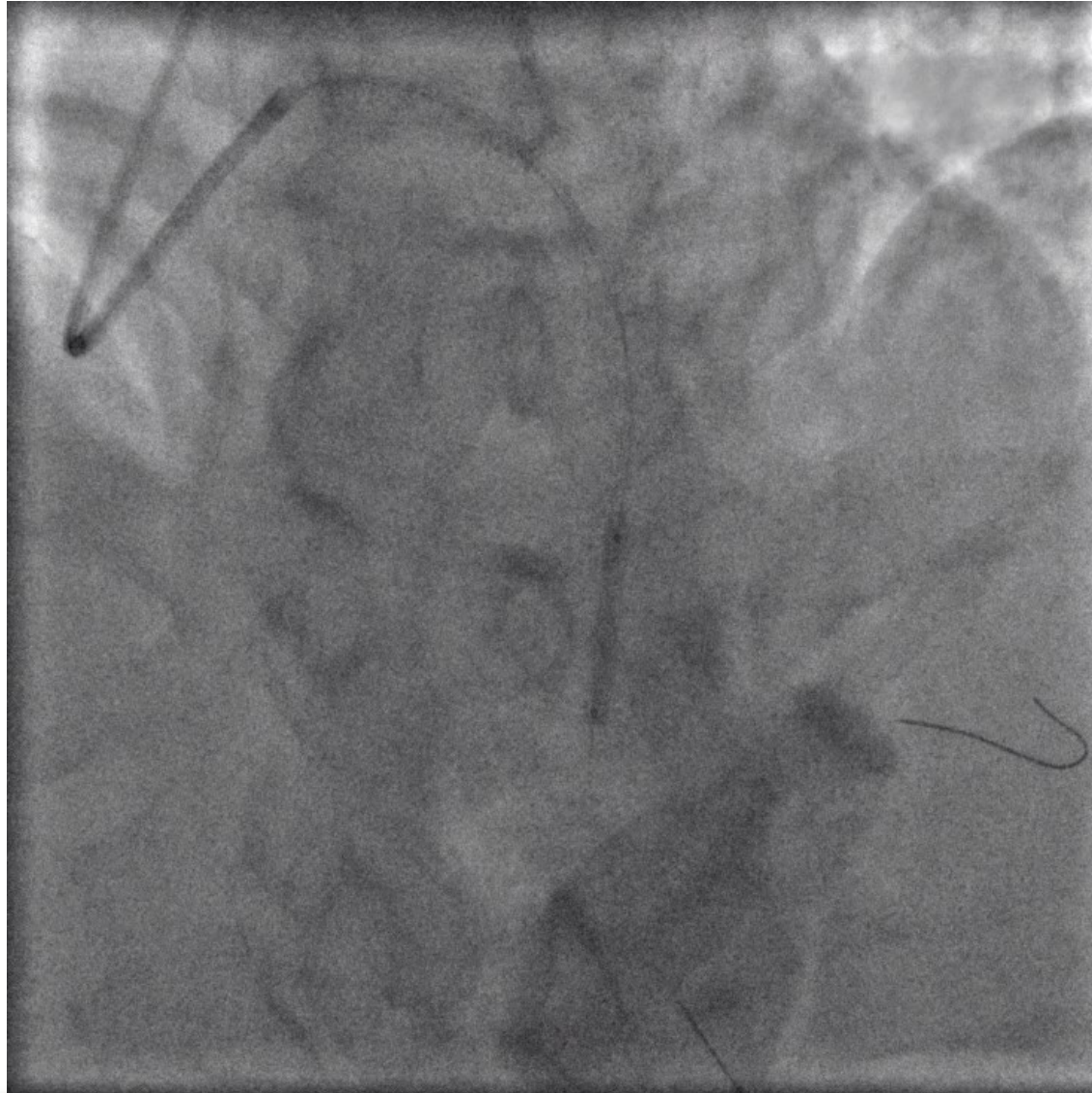






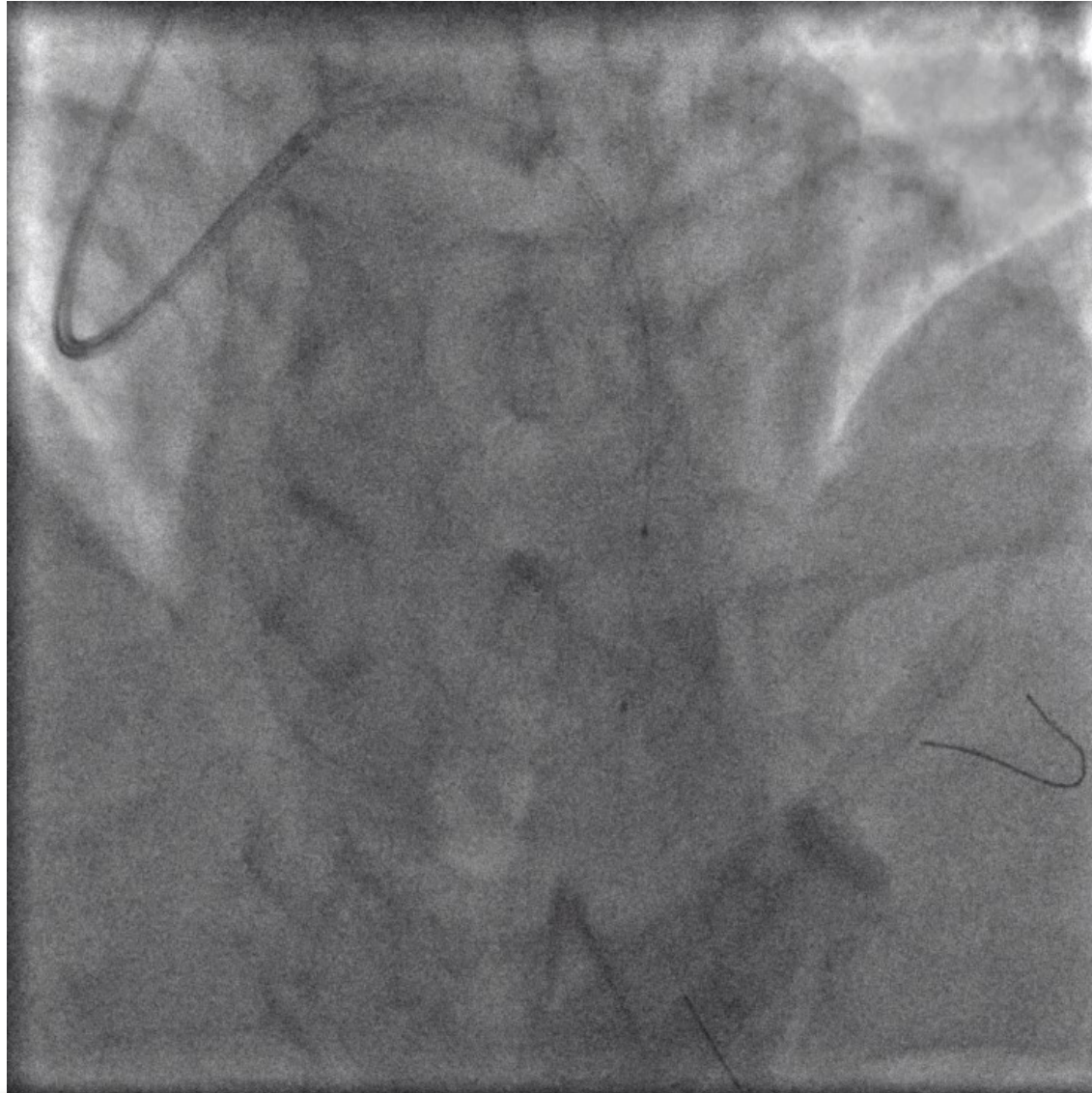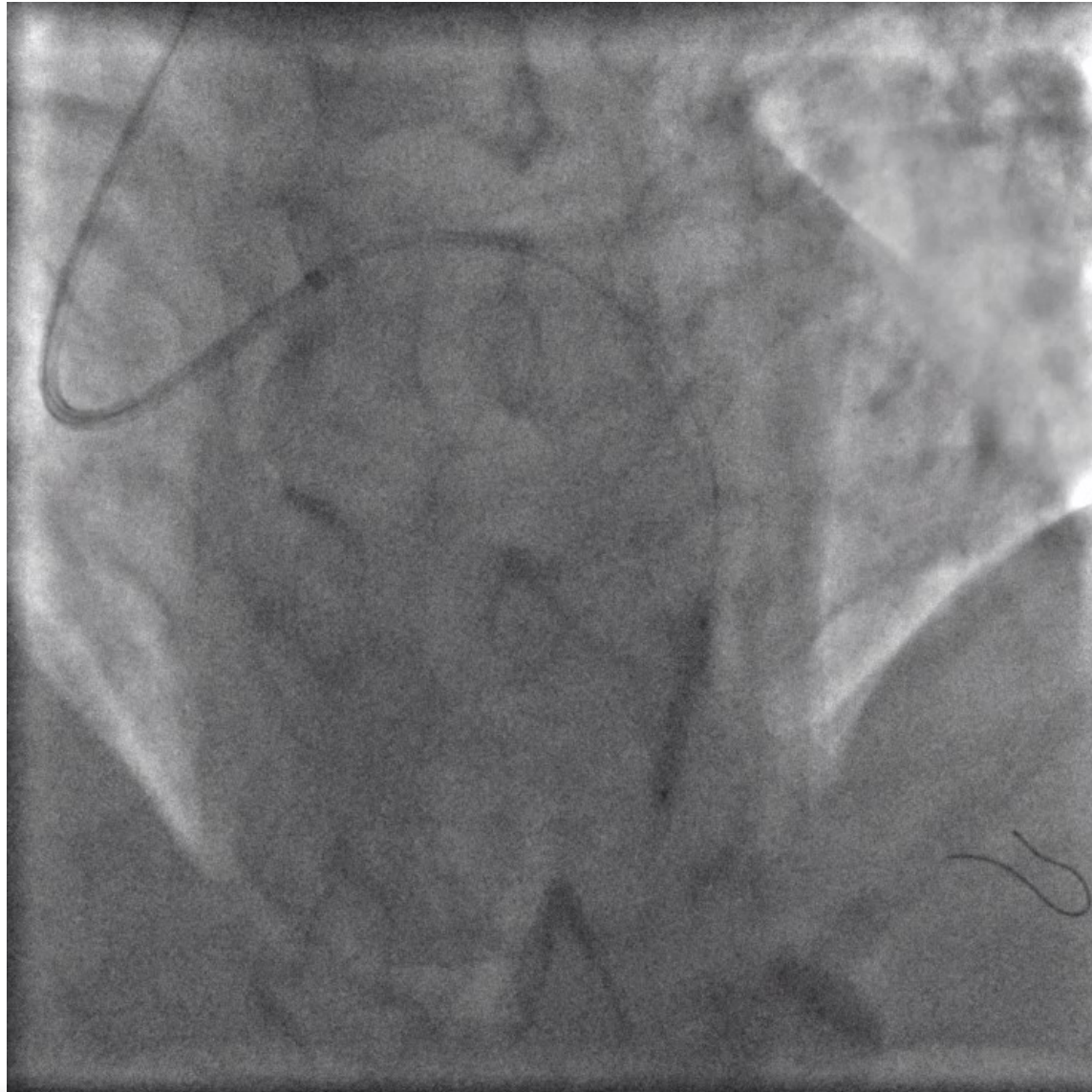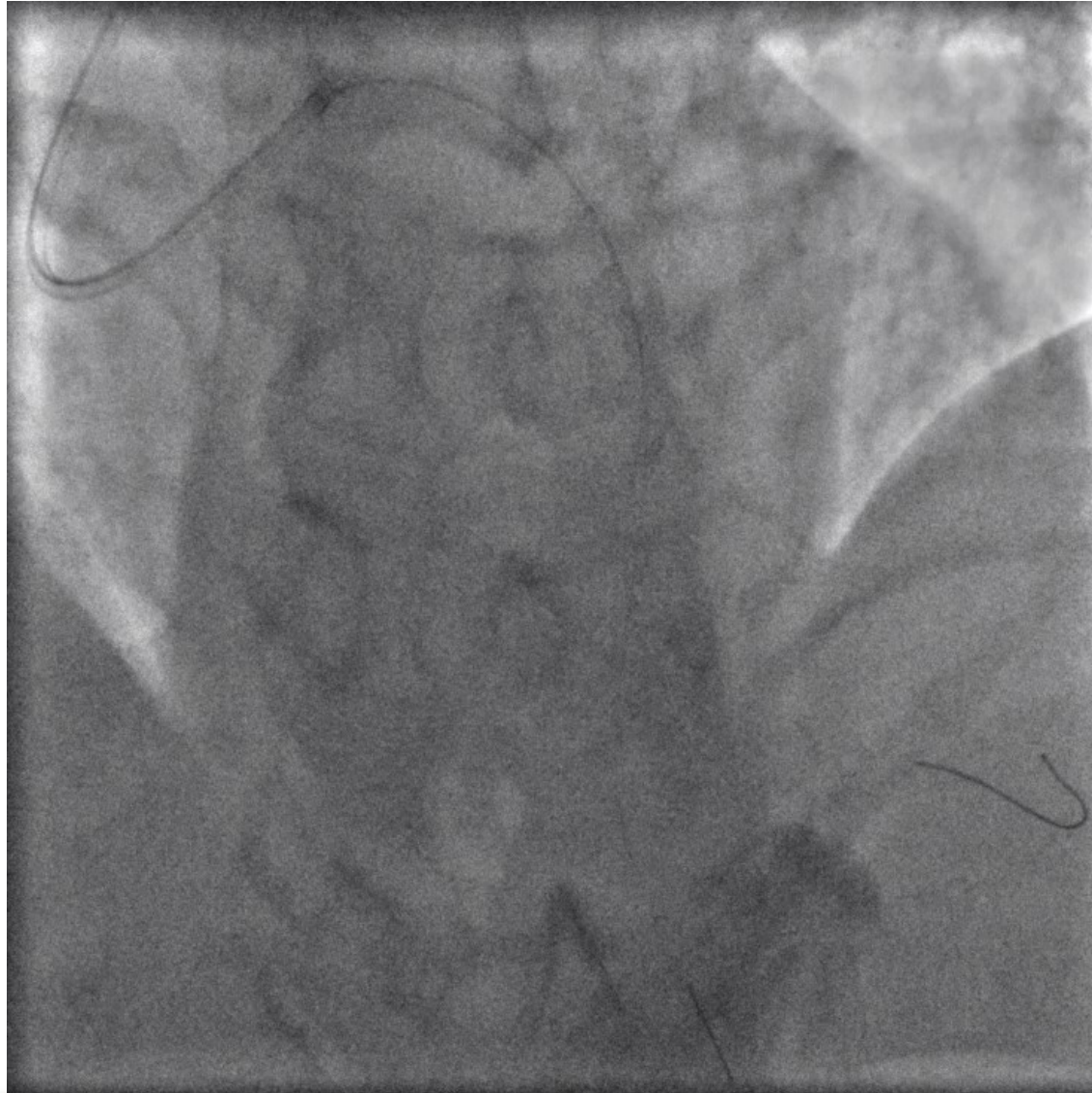


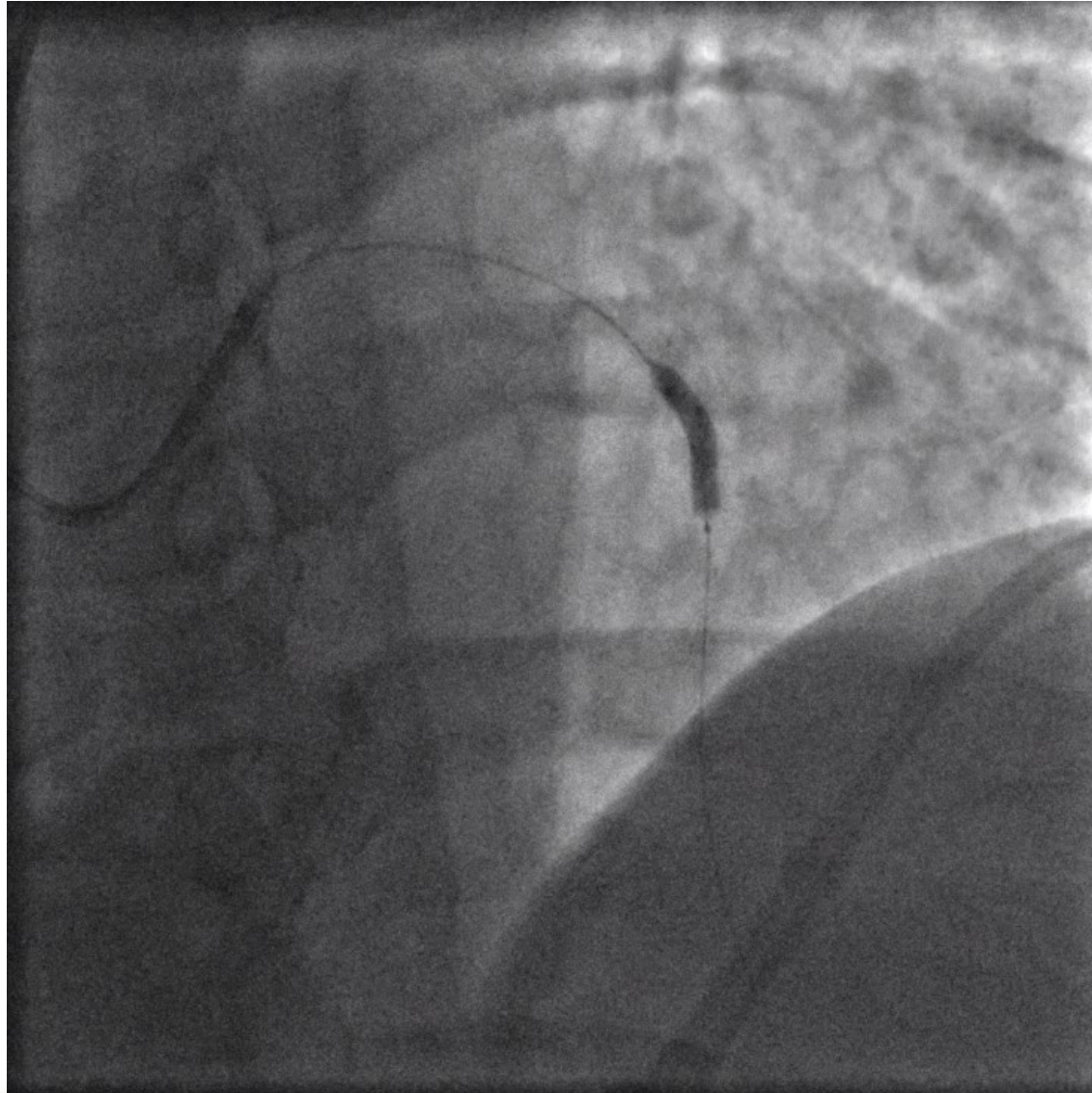




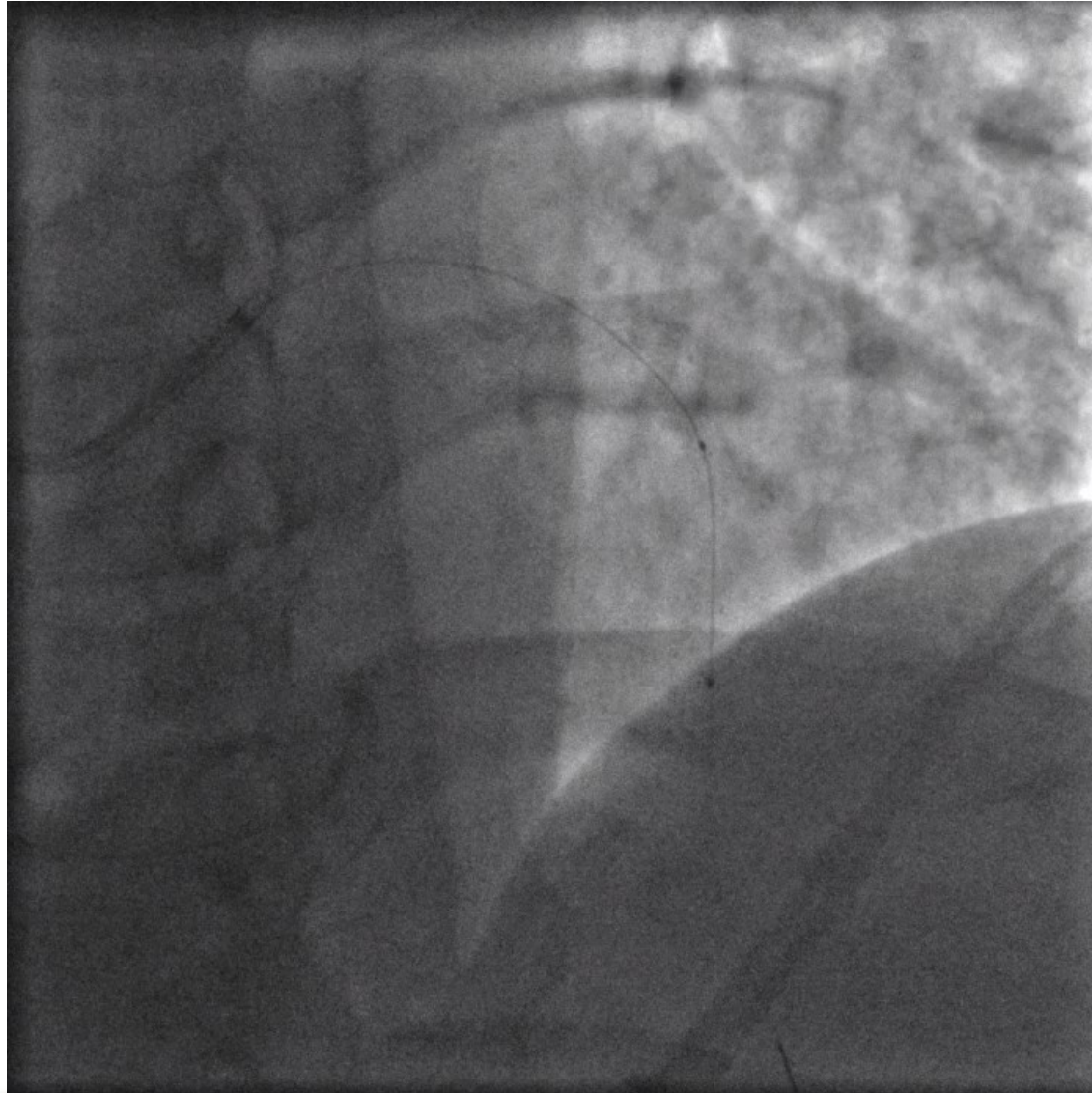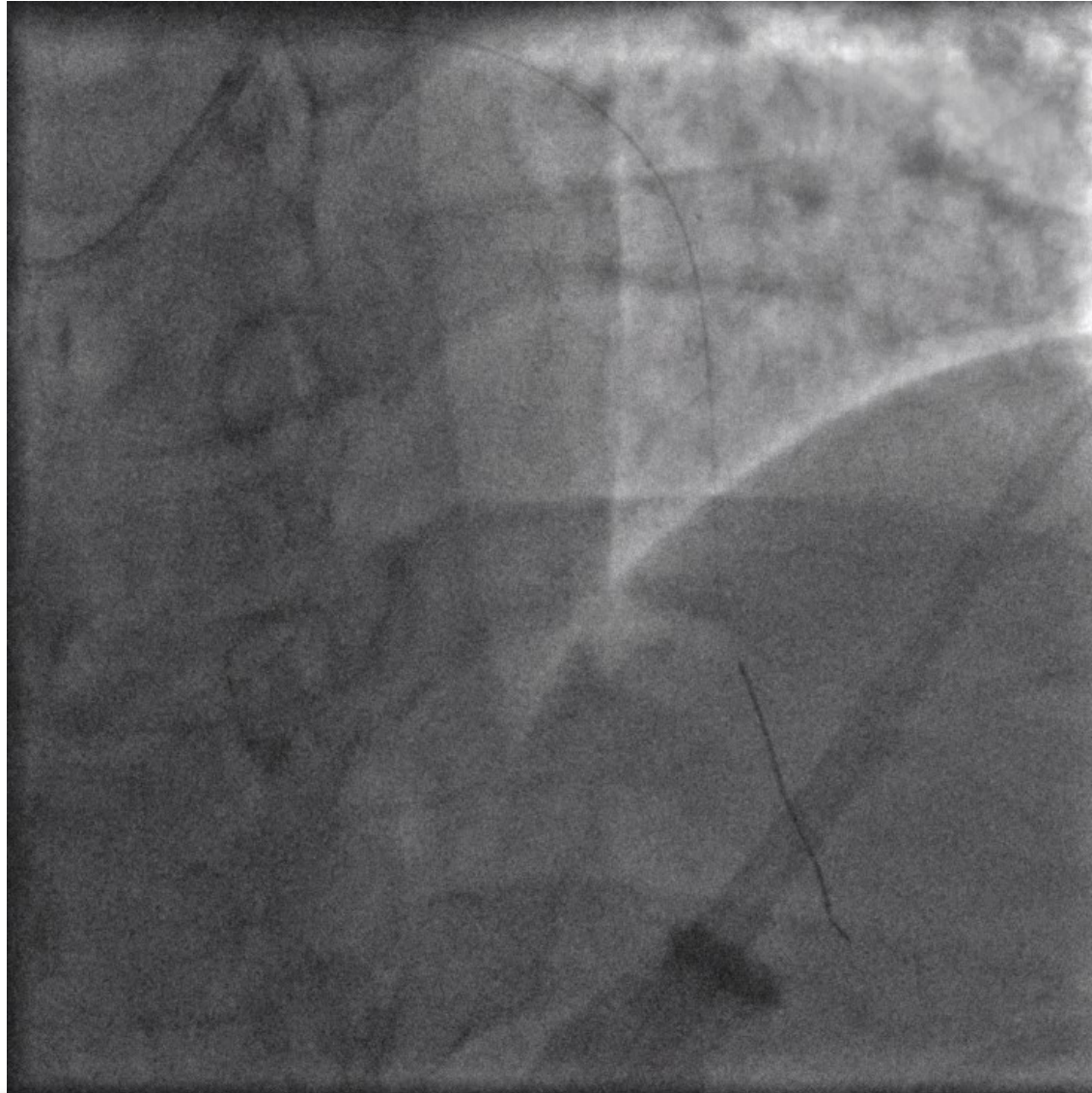








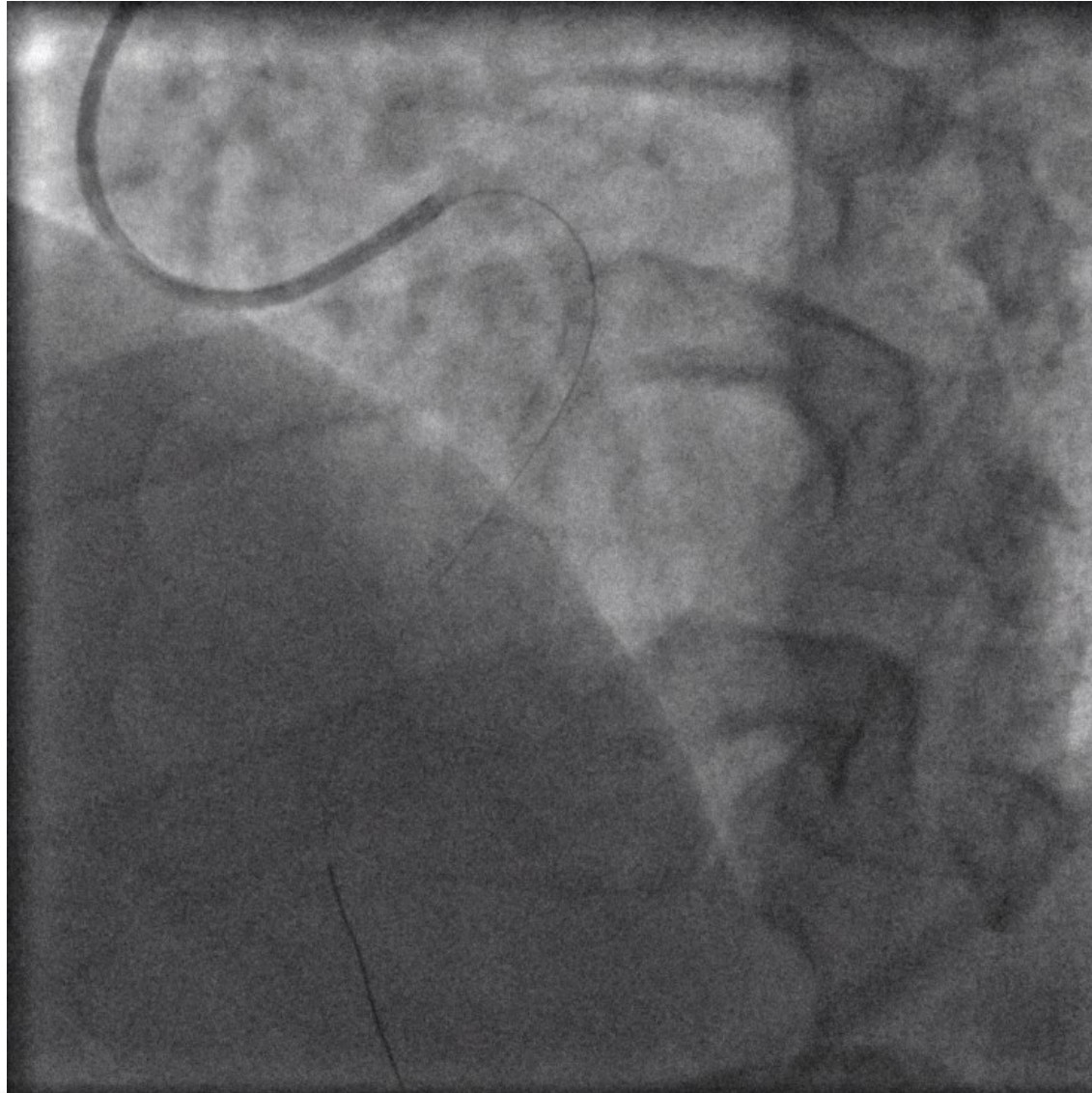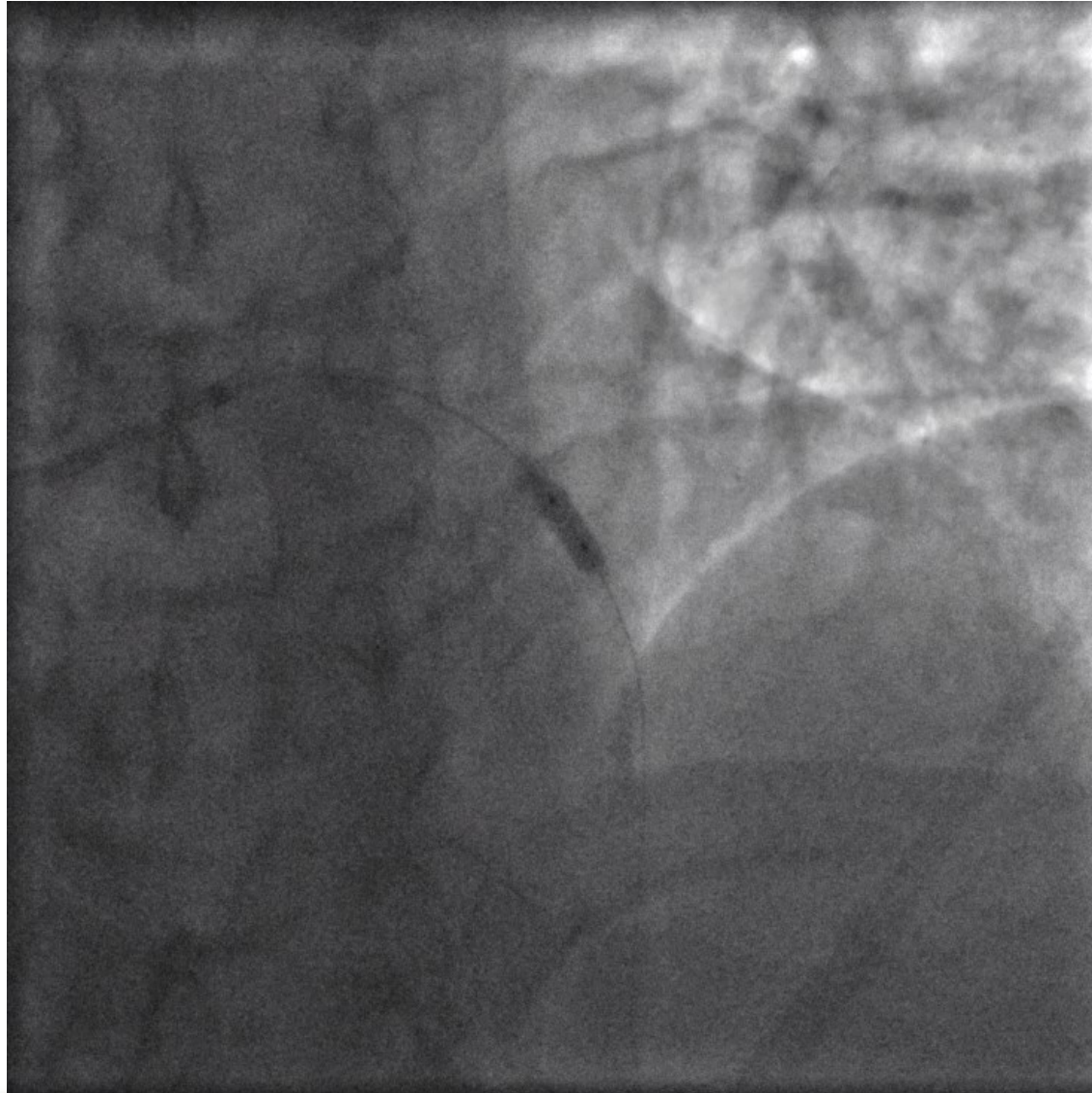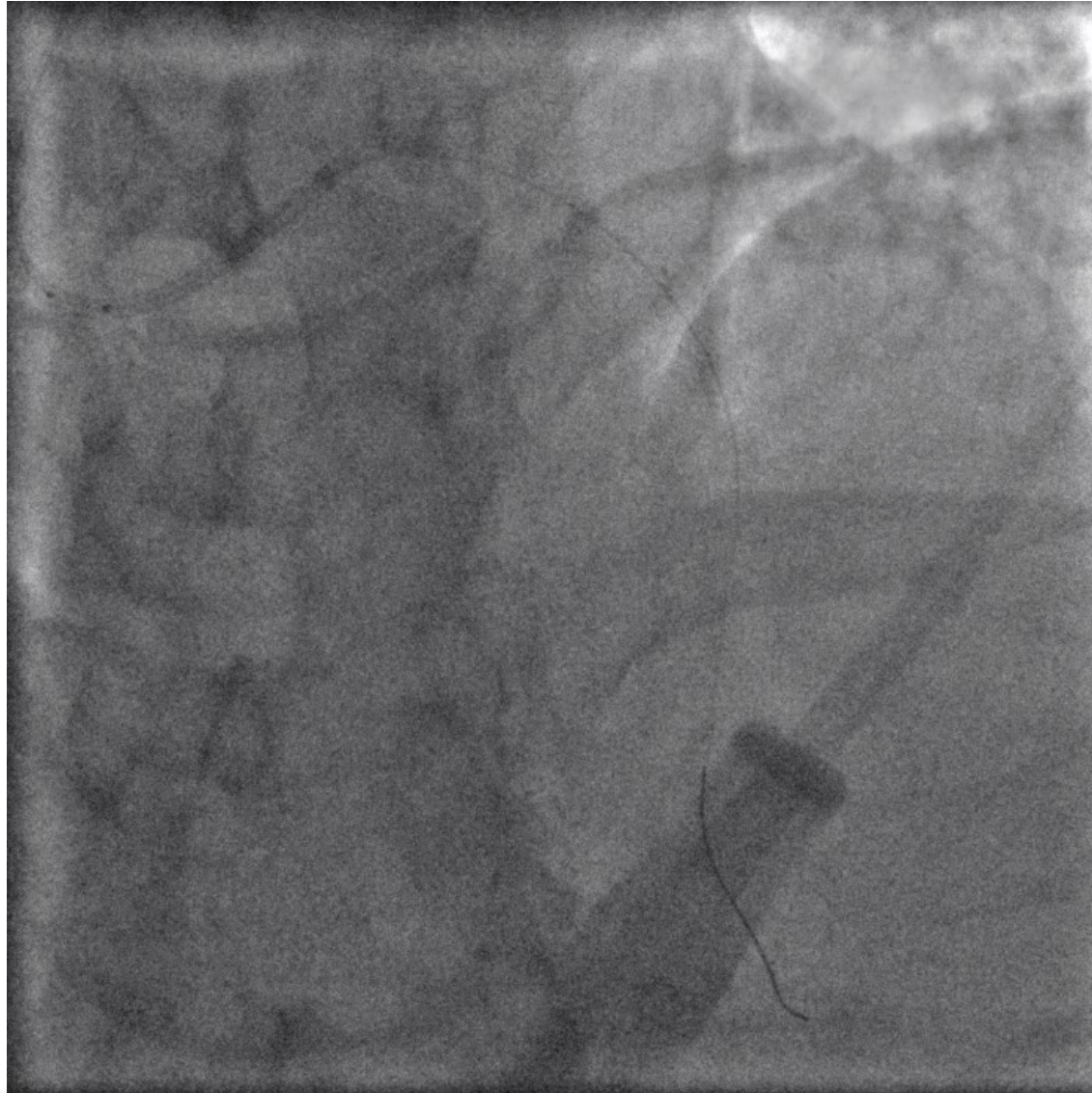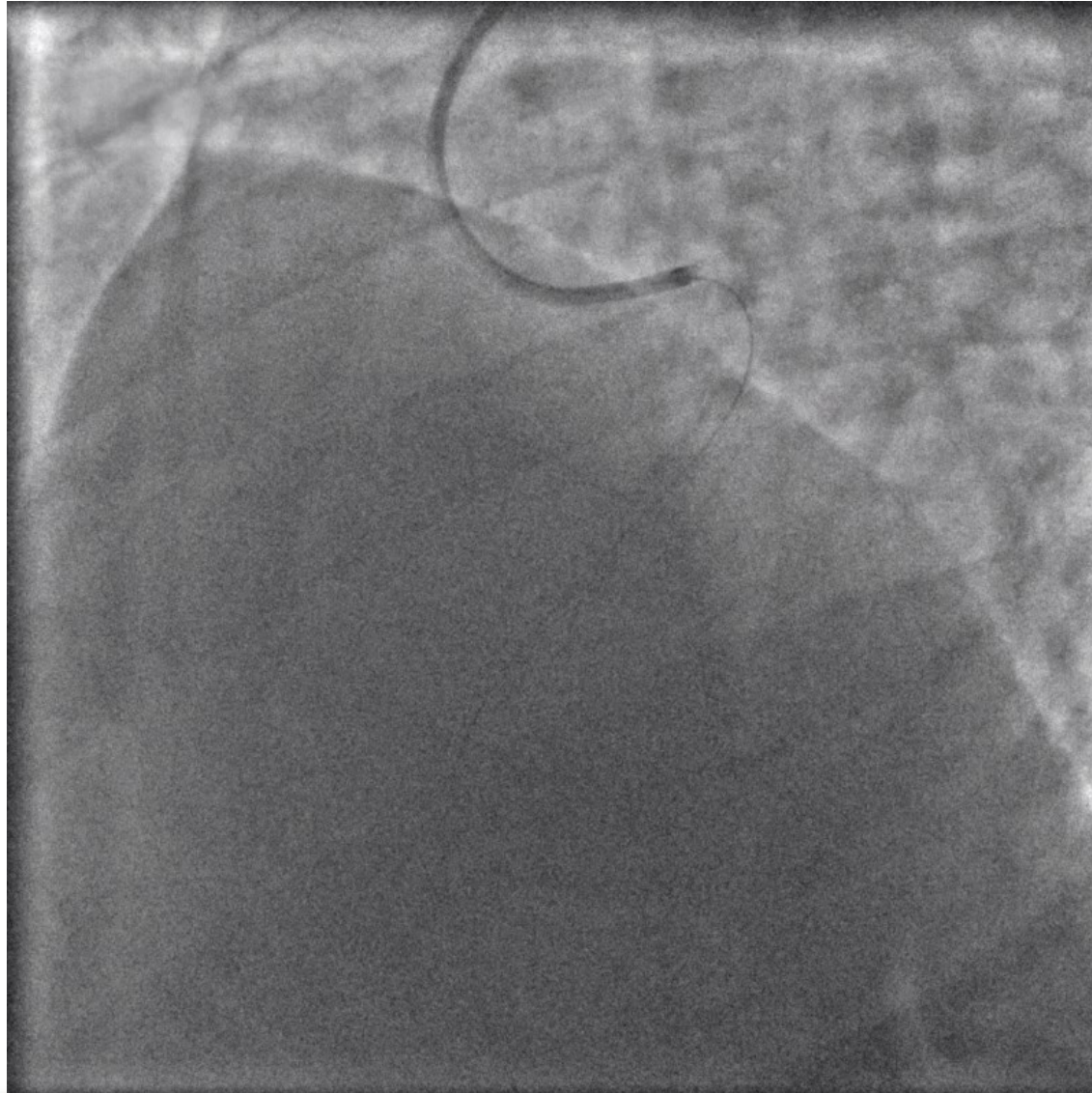






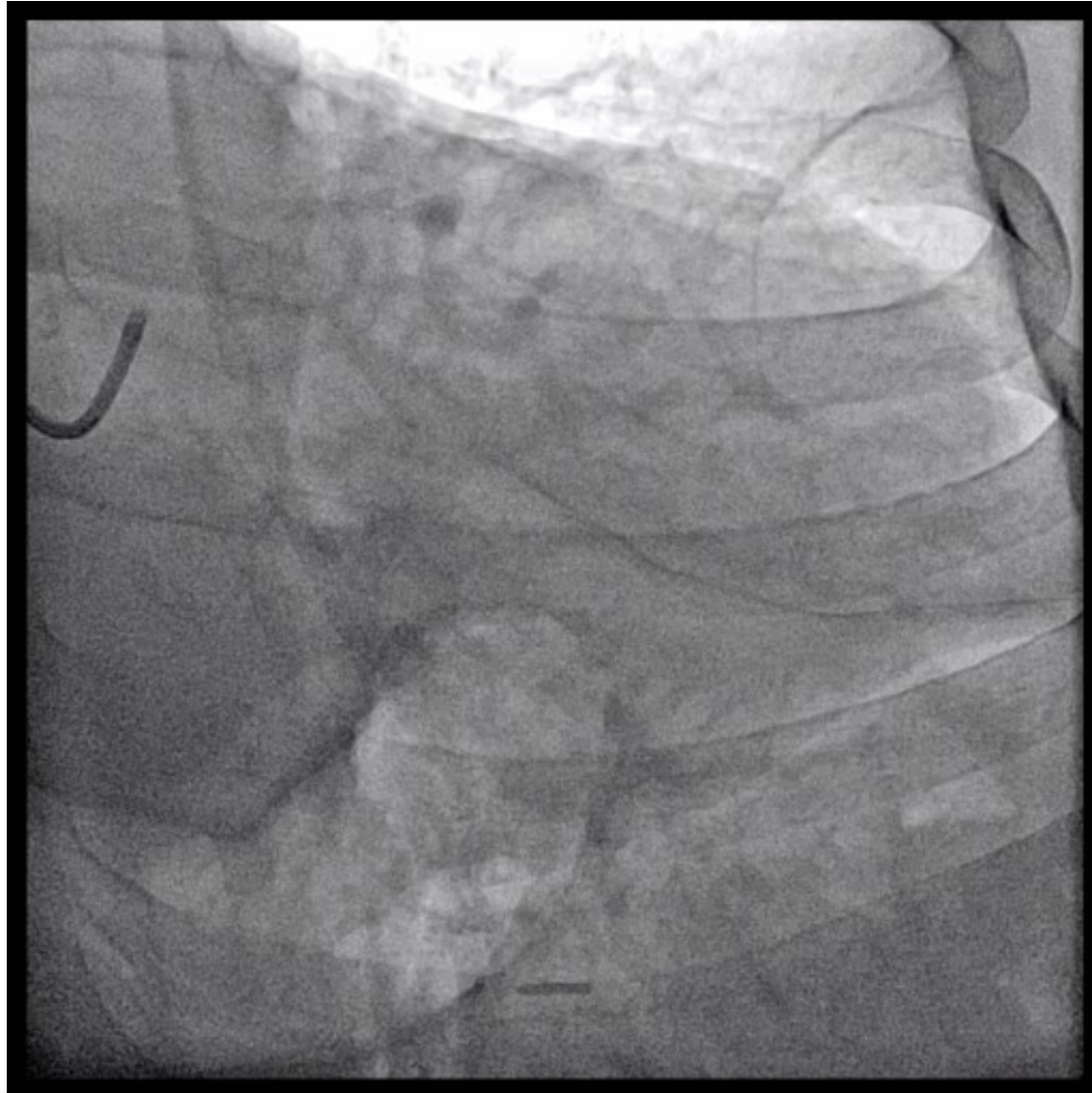


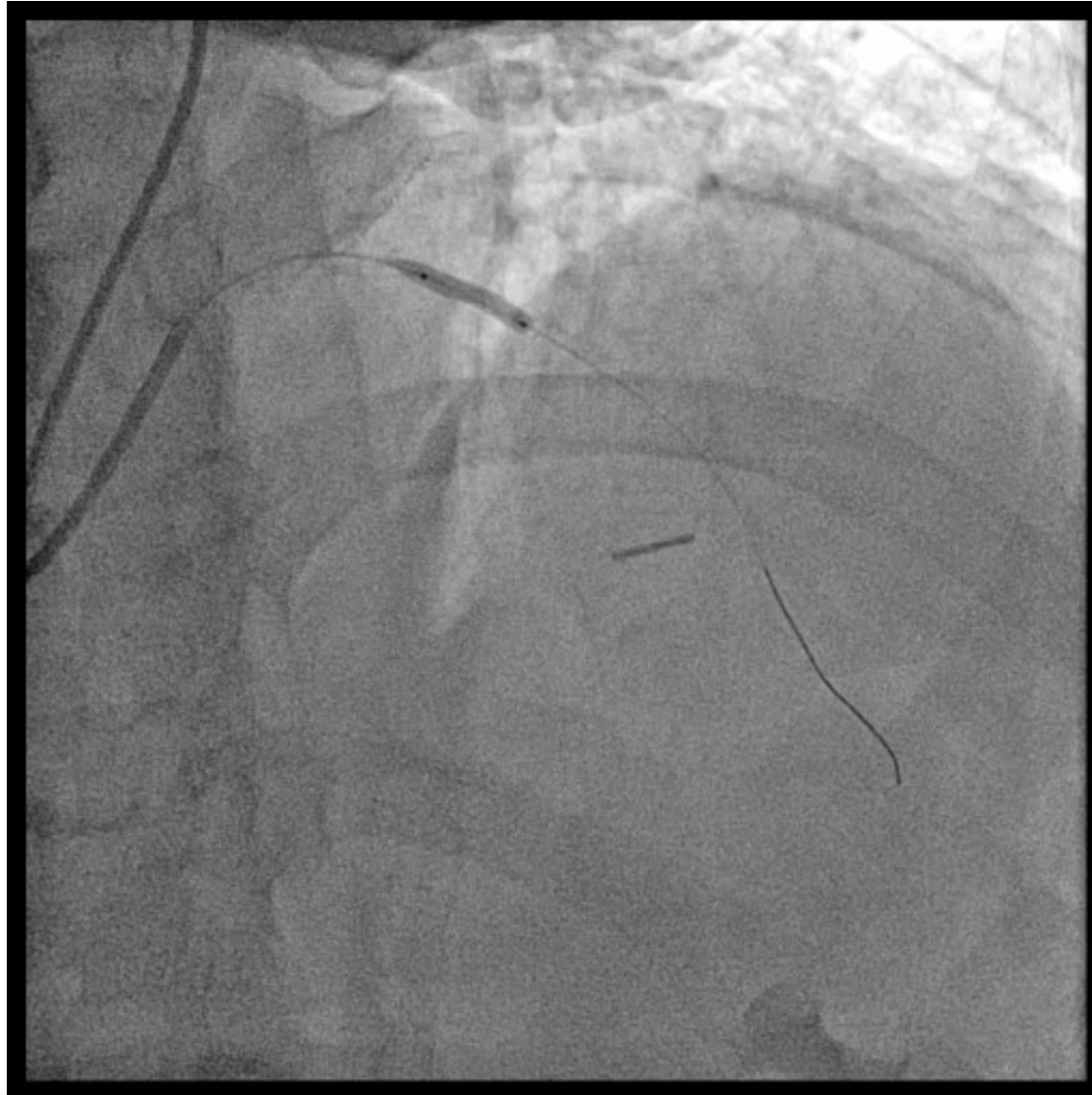


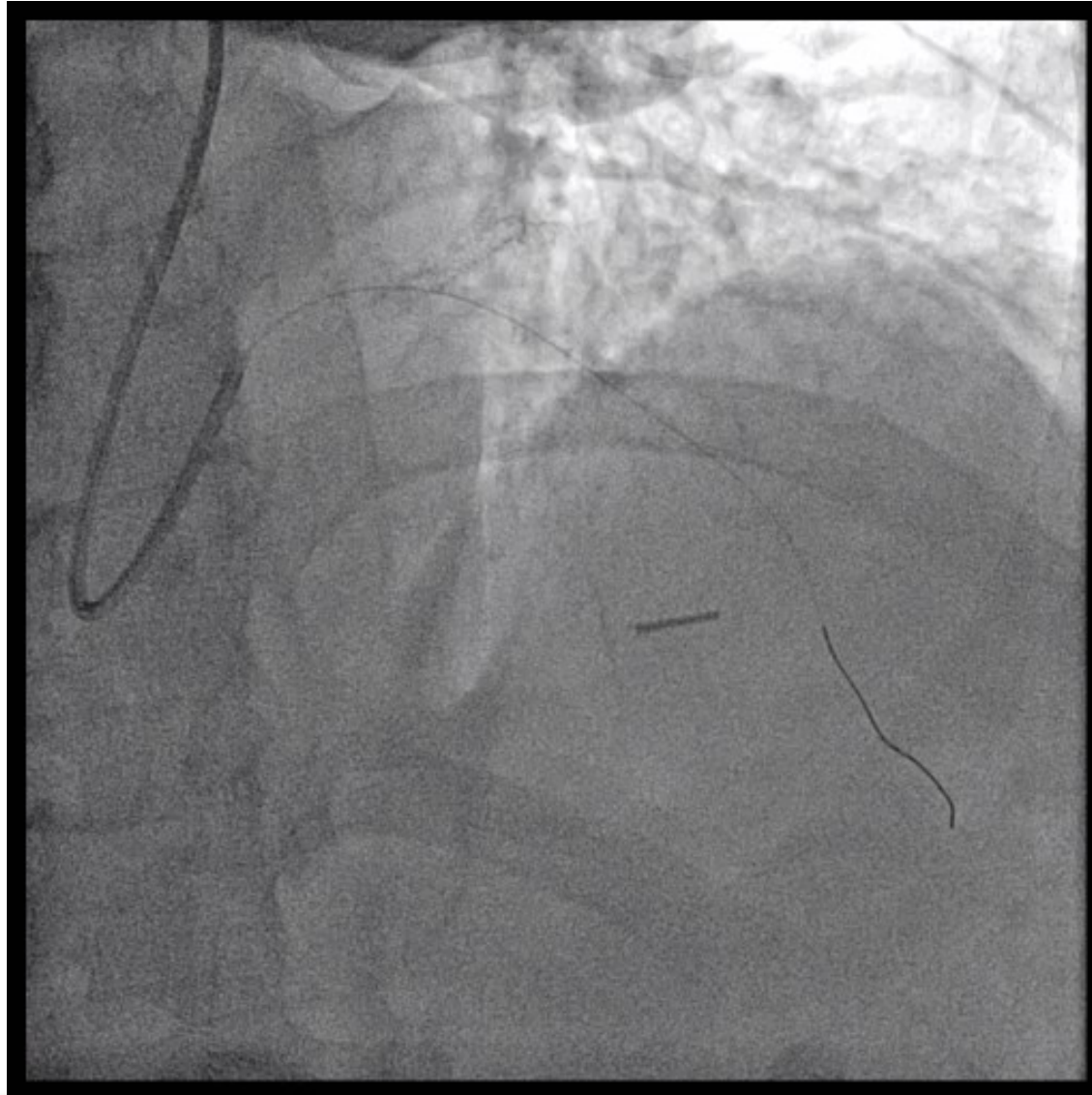


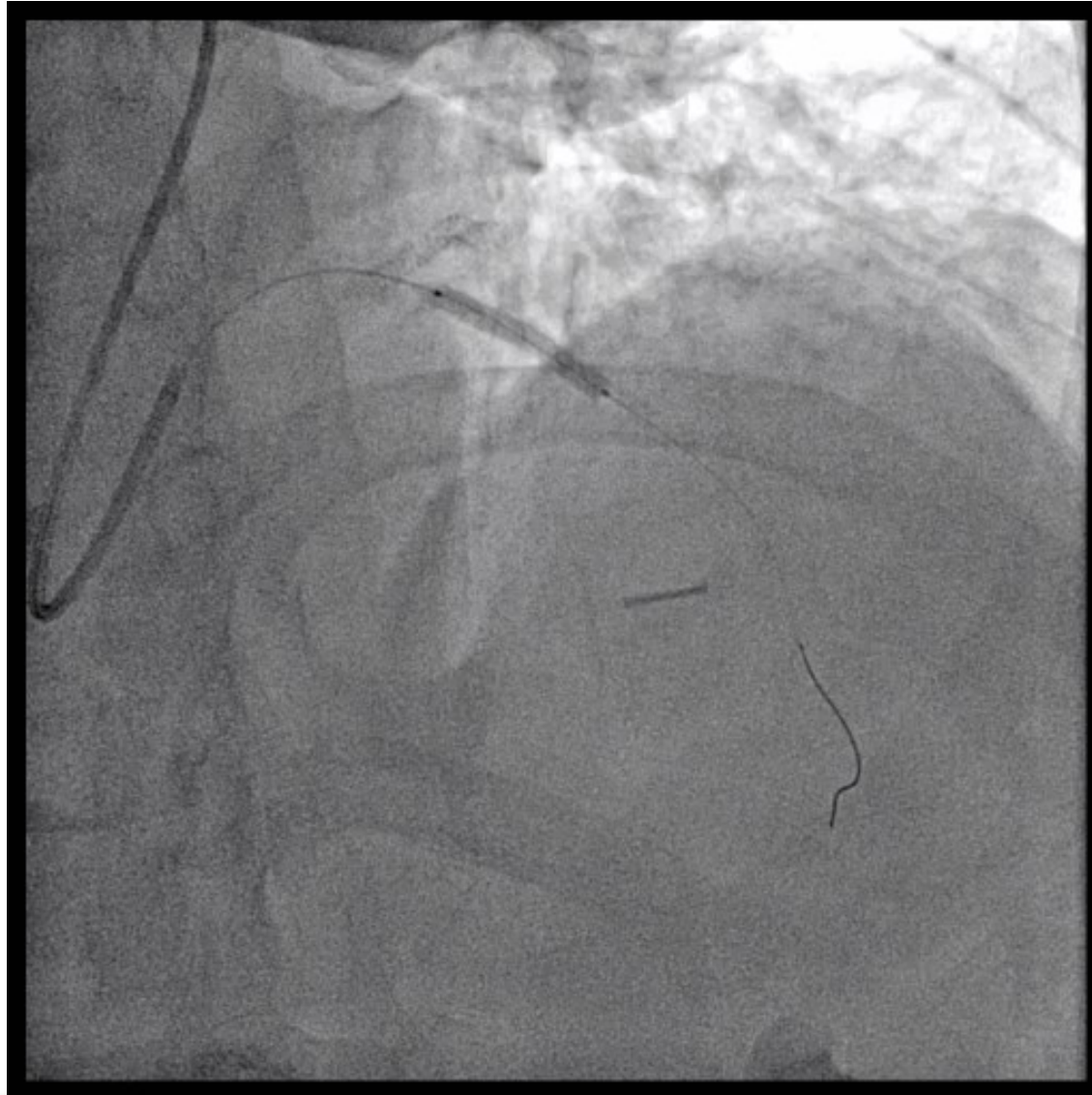
Fantom II (phase IV) registry

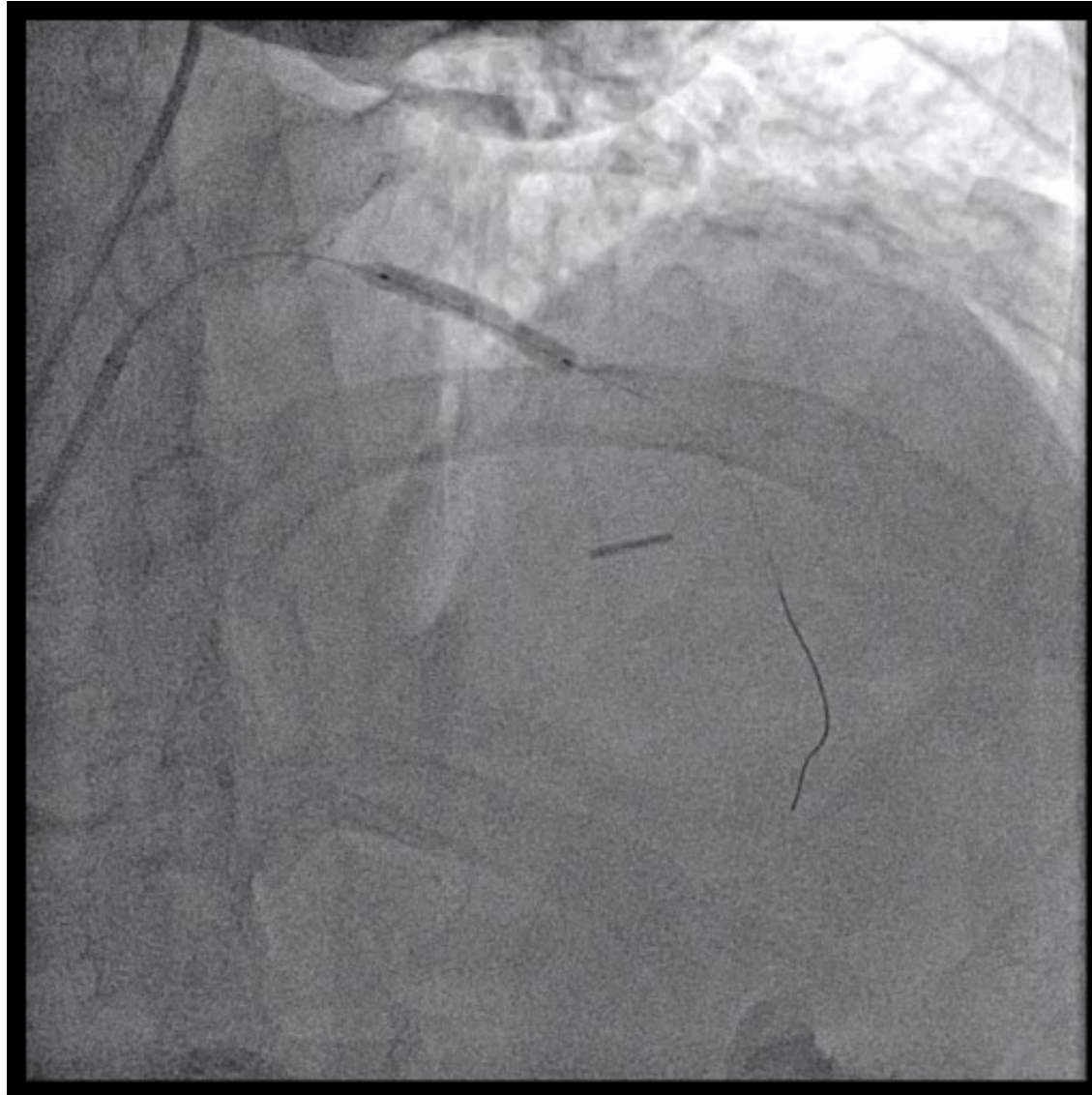
- Male
- Silent ischemia (stress MRI)
- 58 yo
- 71 kg 160 cms
- Dyslipidemia, HTN, smoking

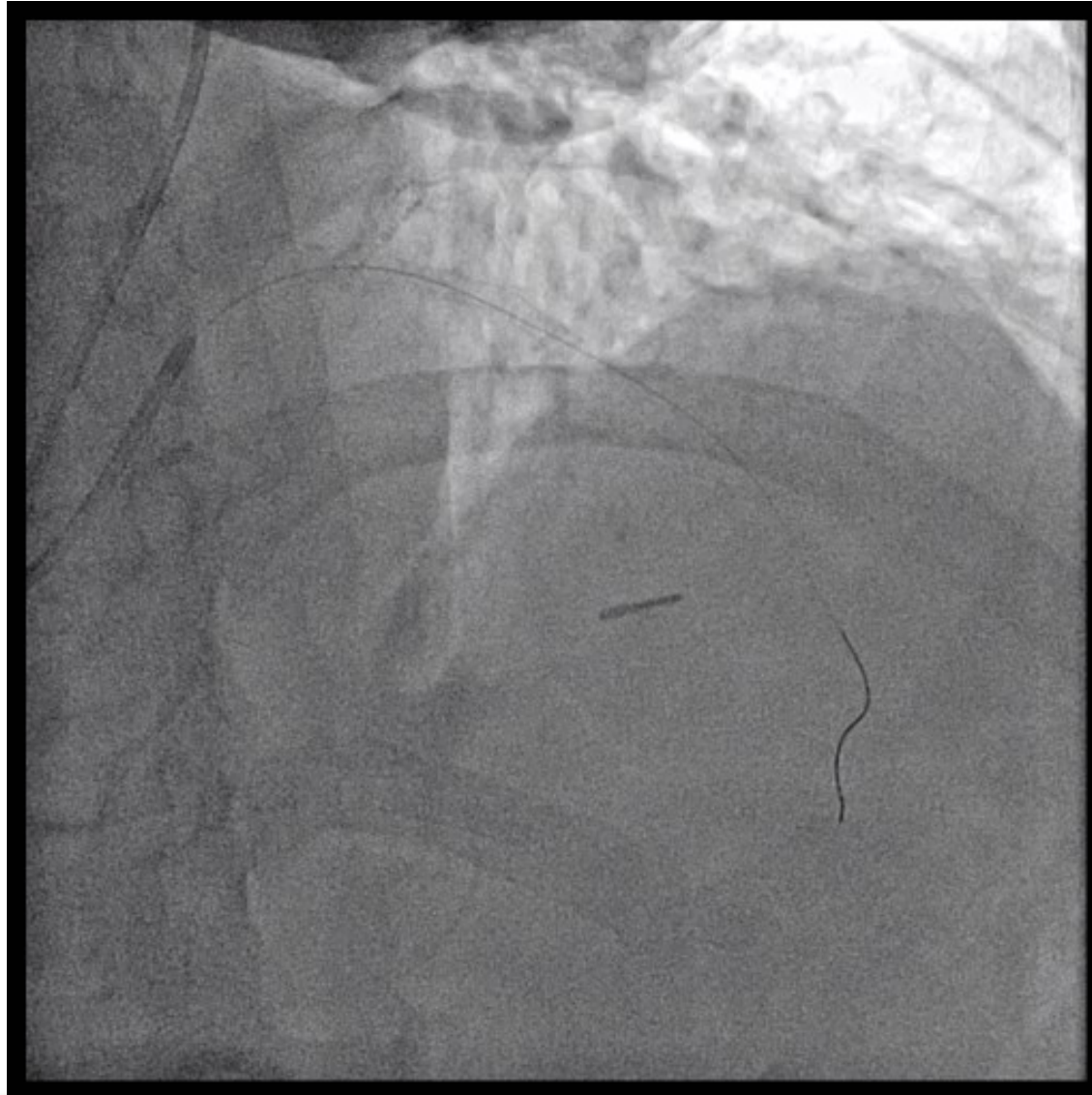


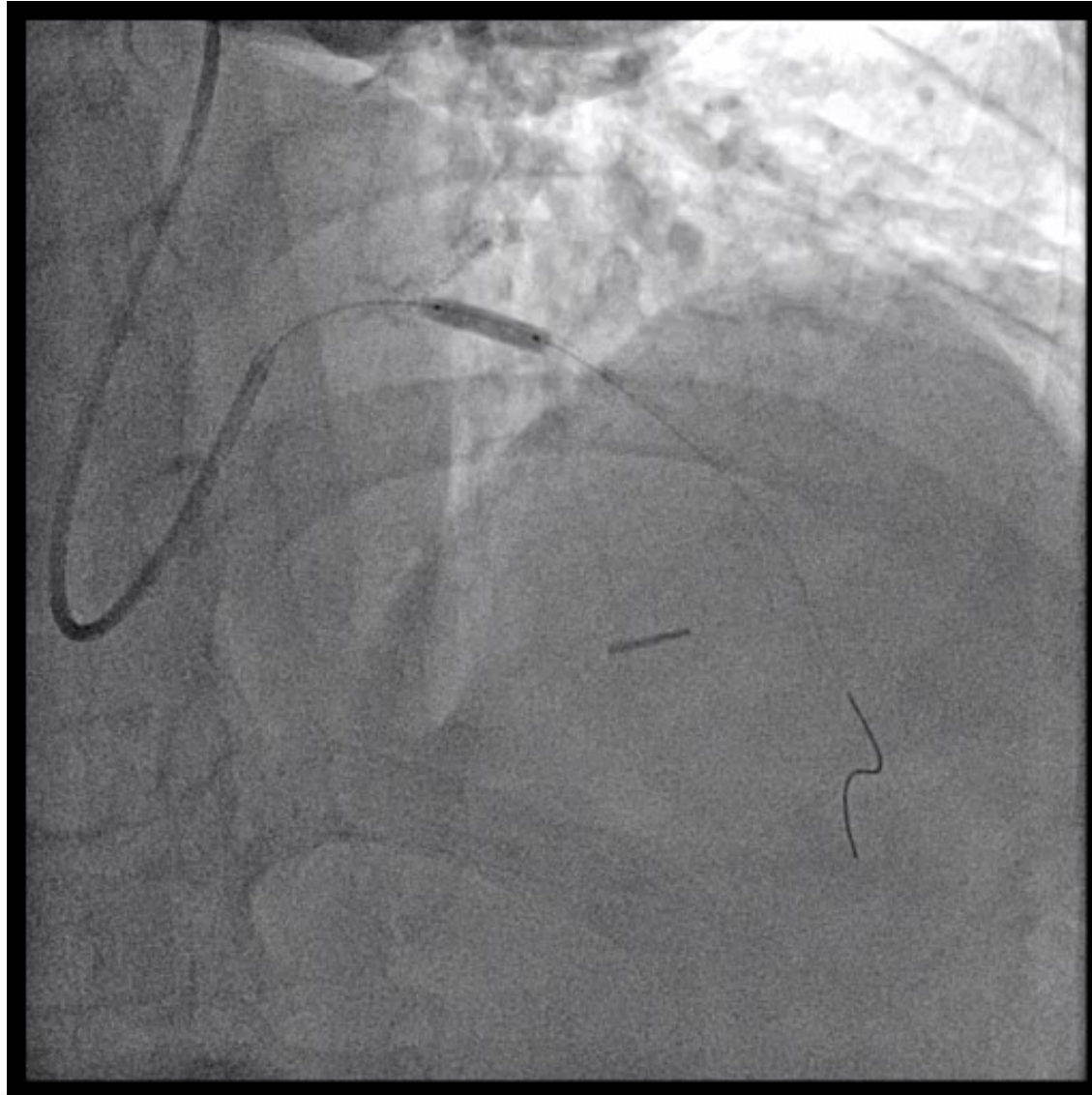


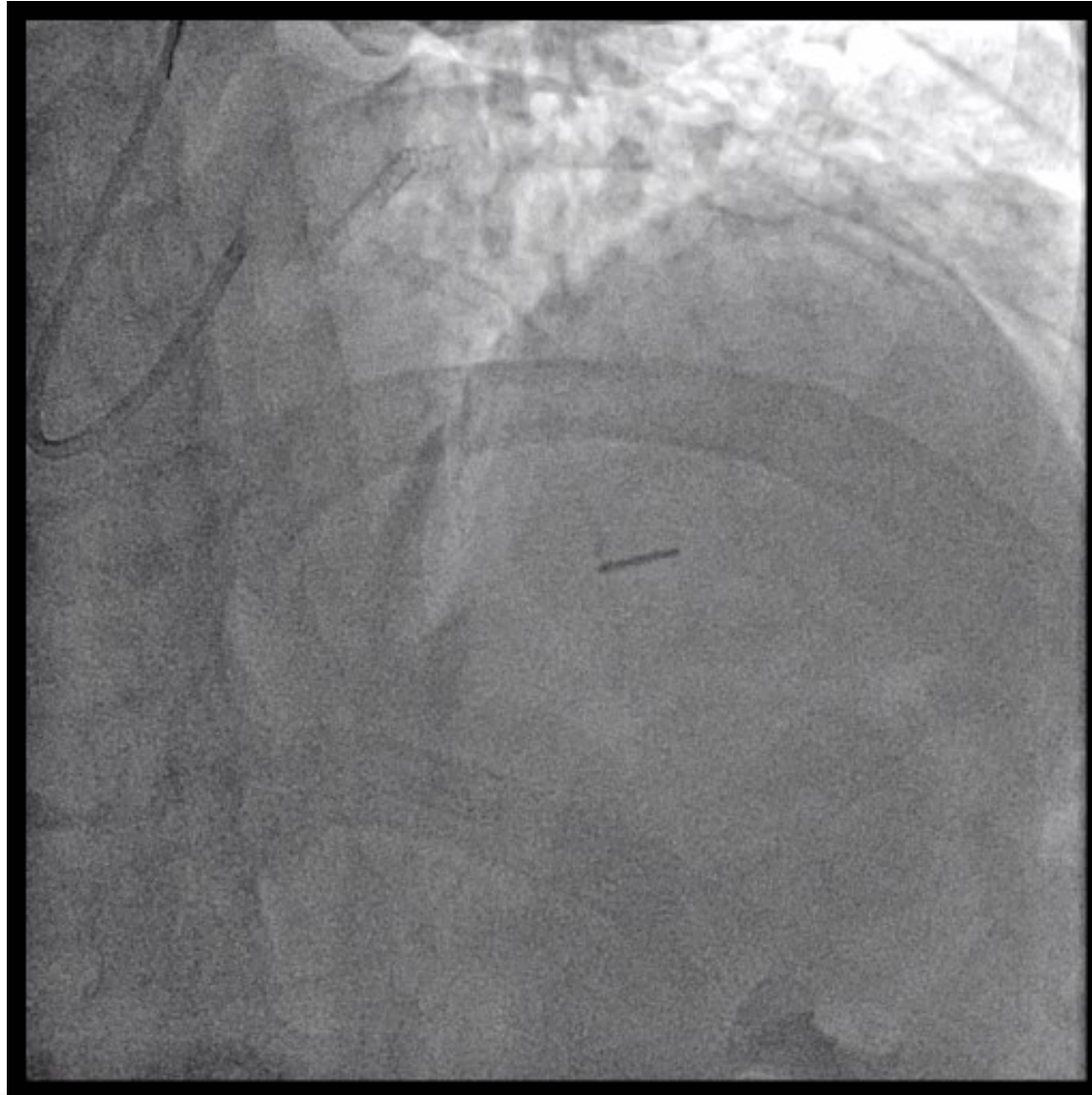


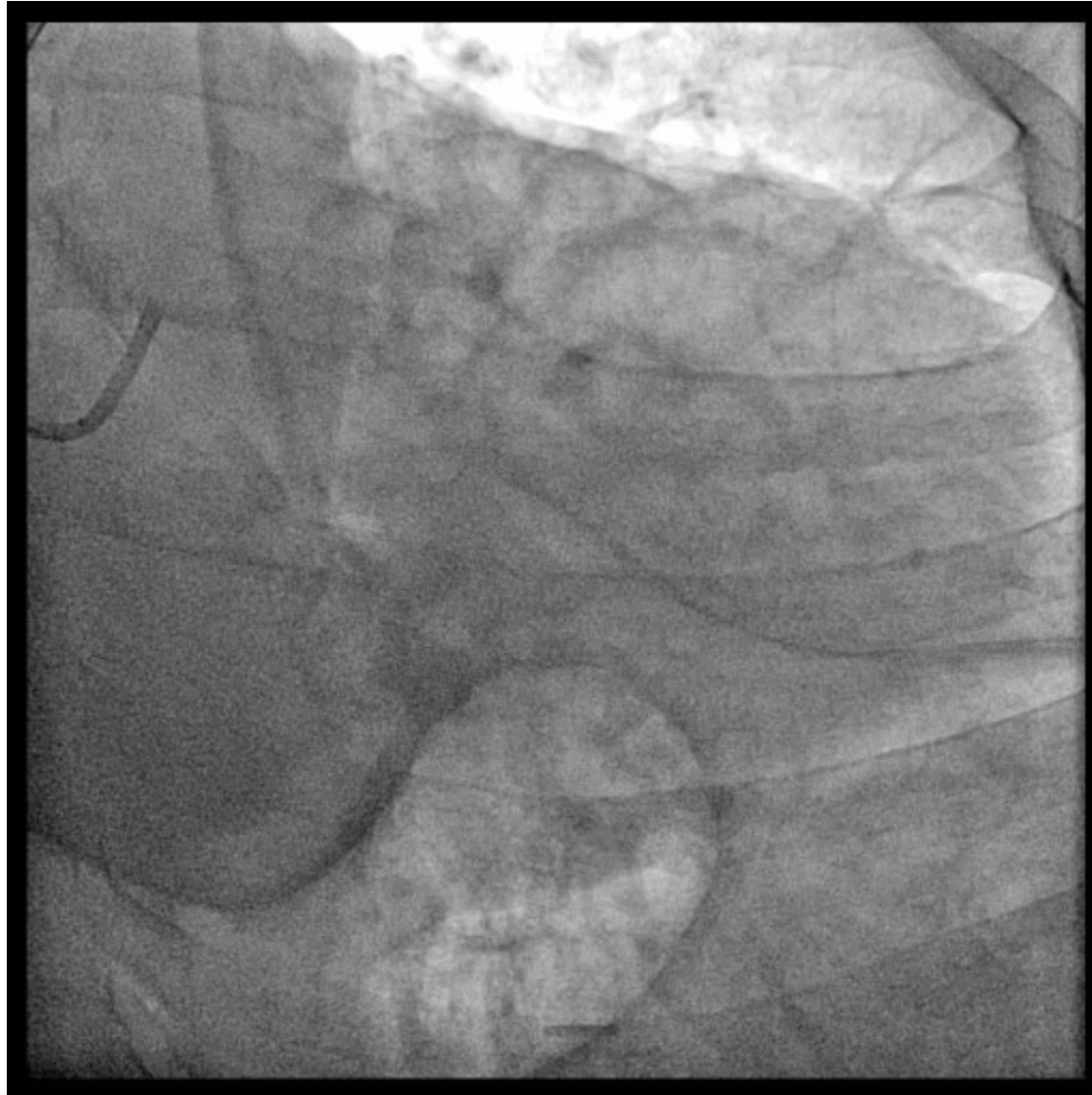

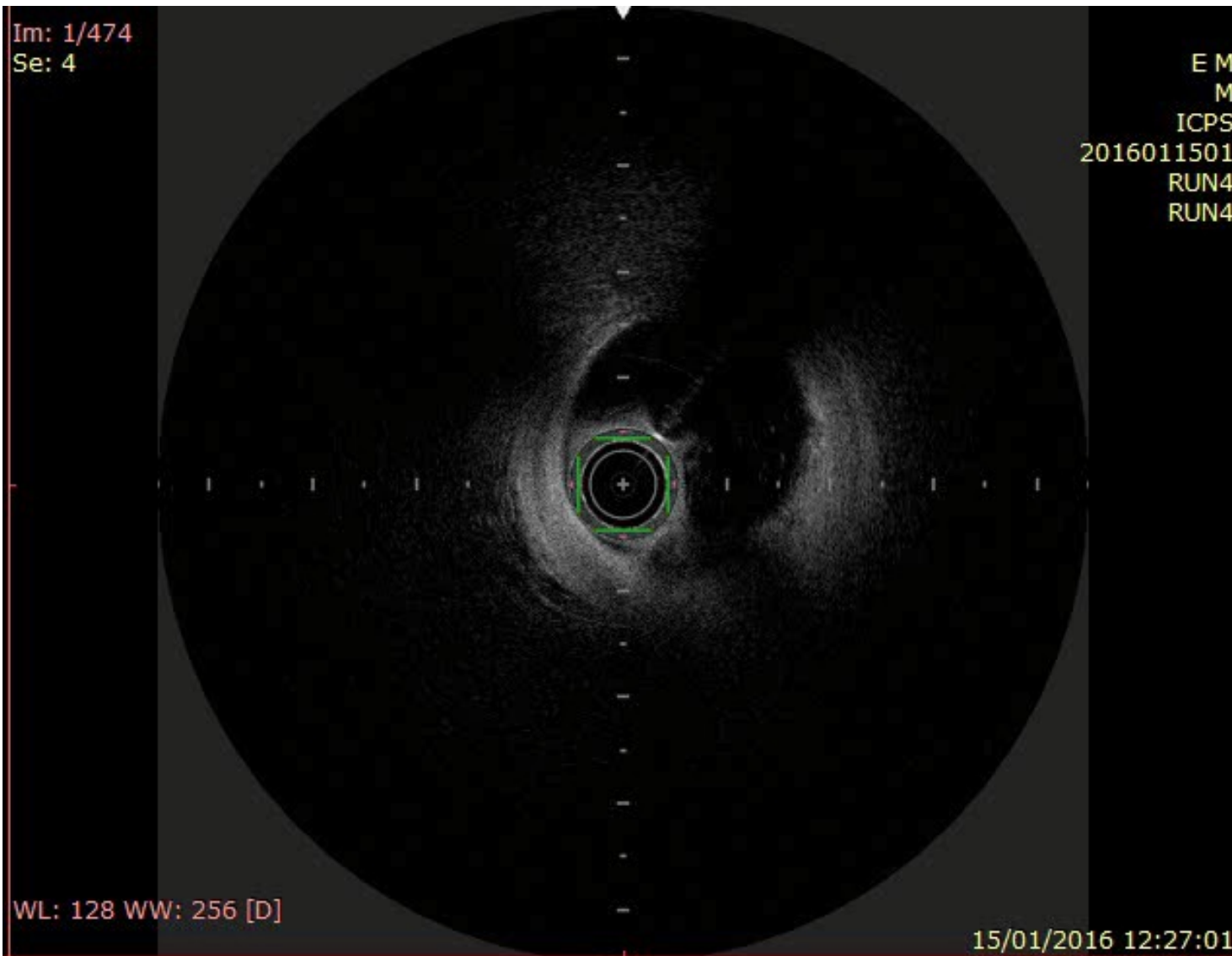


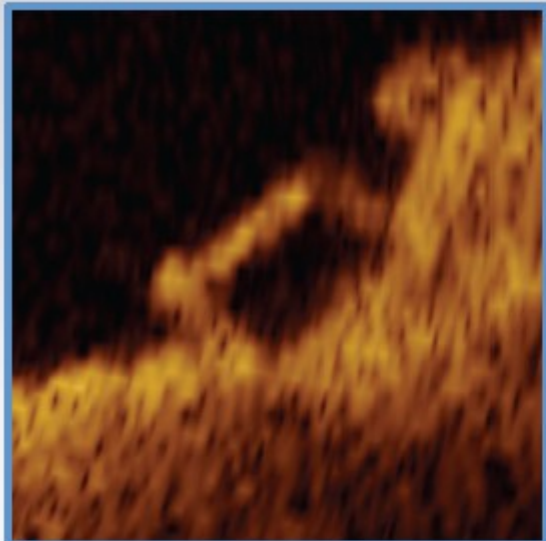




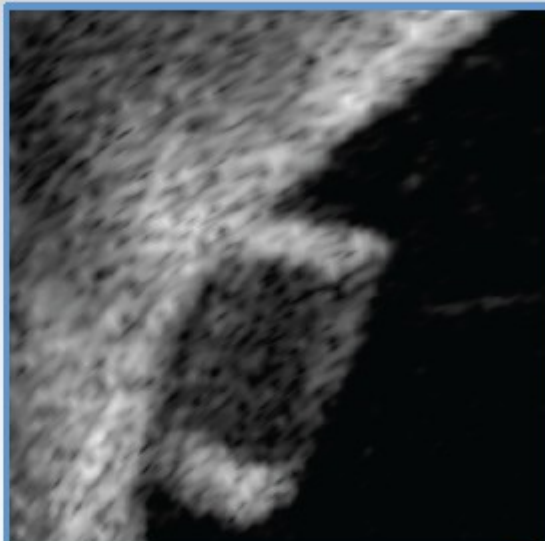




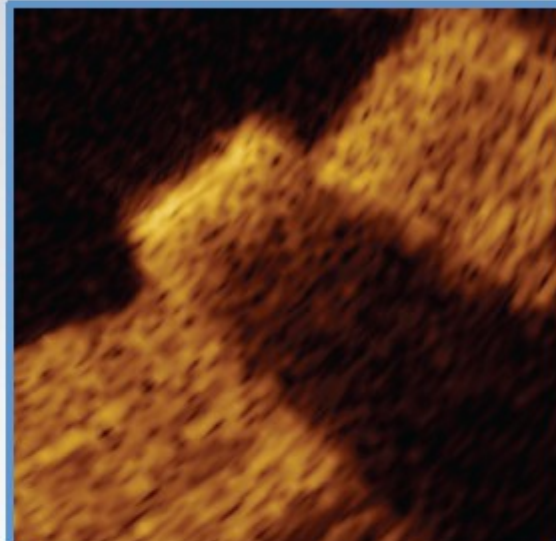




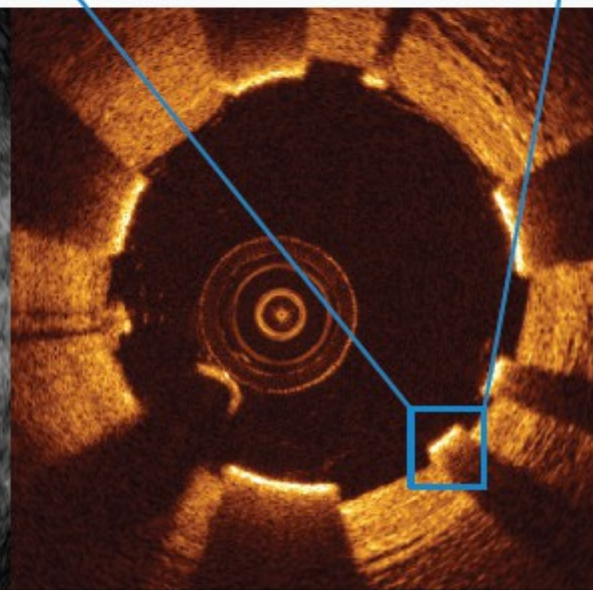
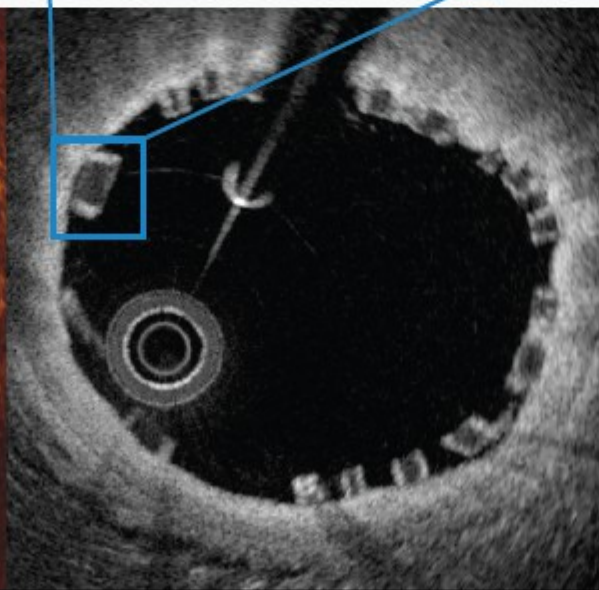
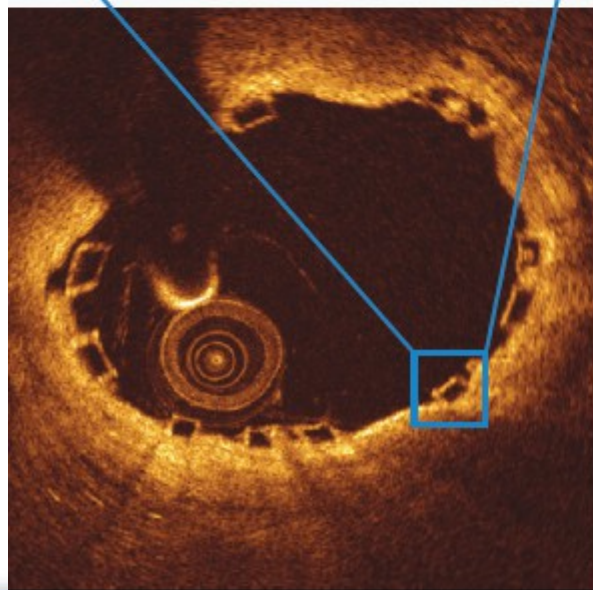
ABSORB



DESolve

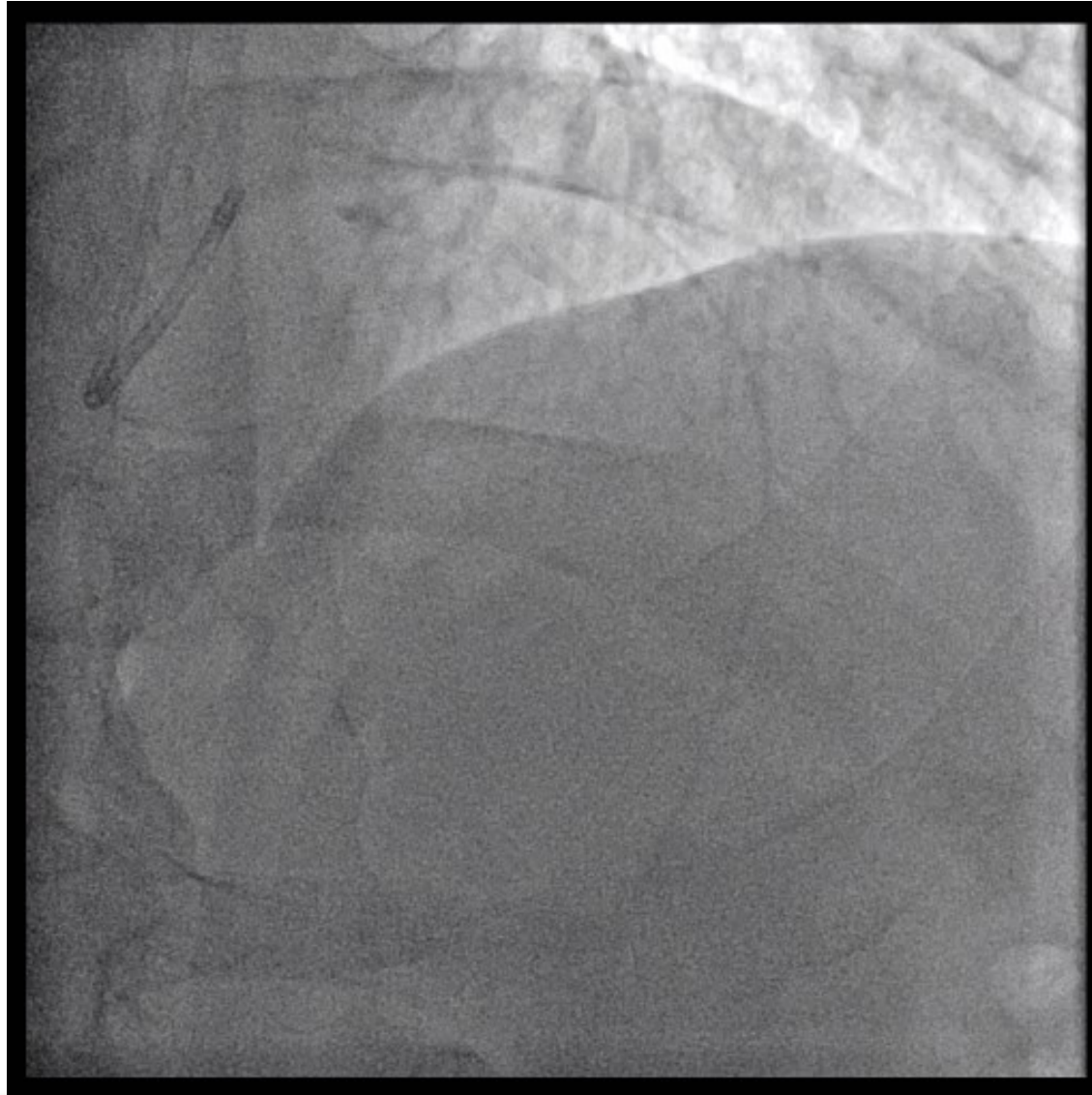

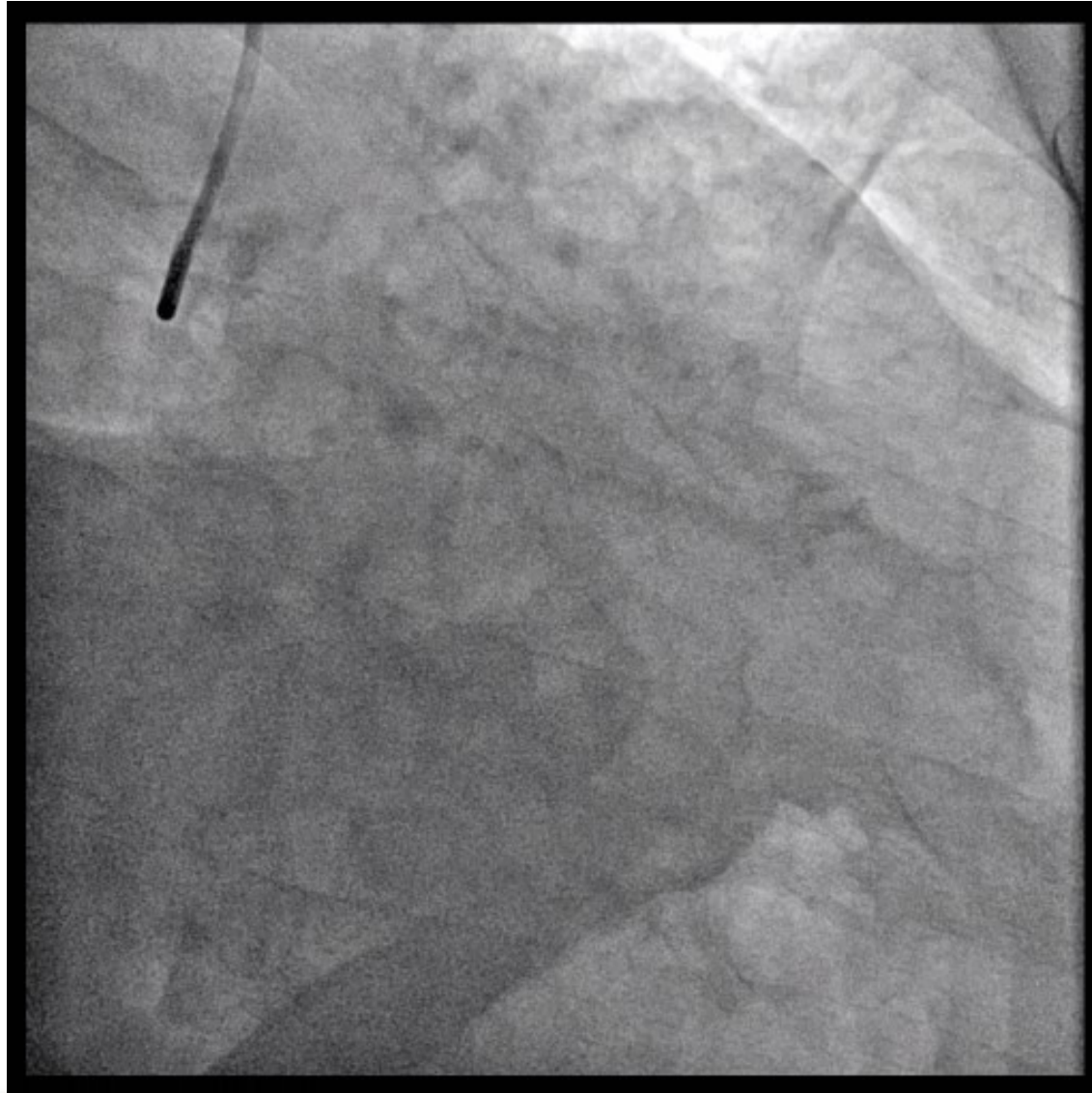FANTOM

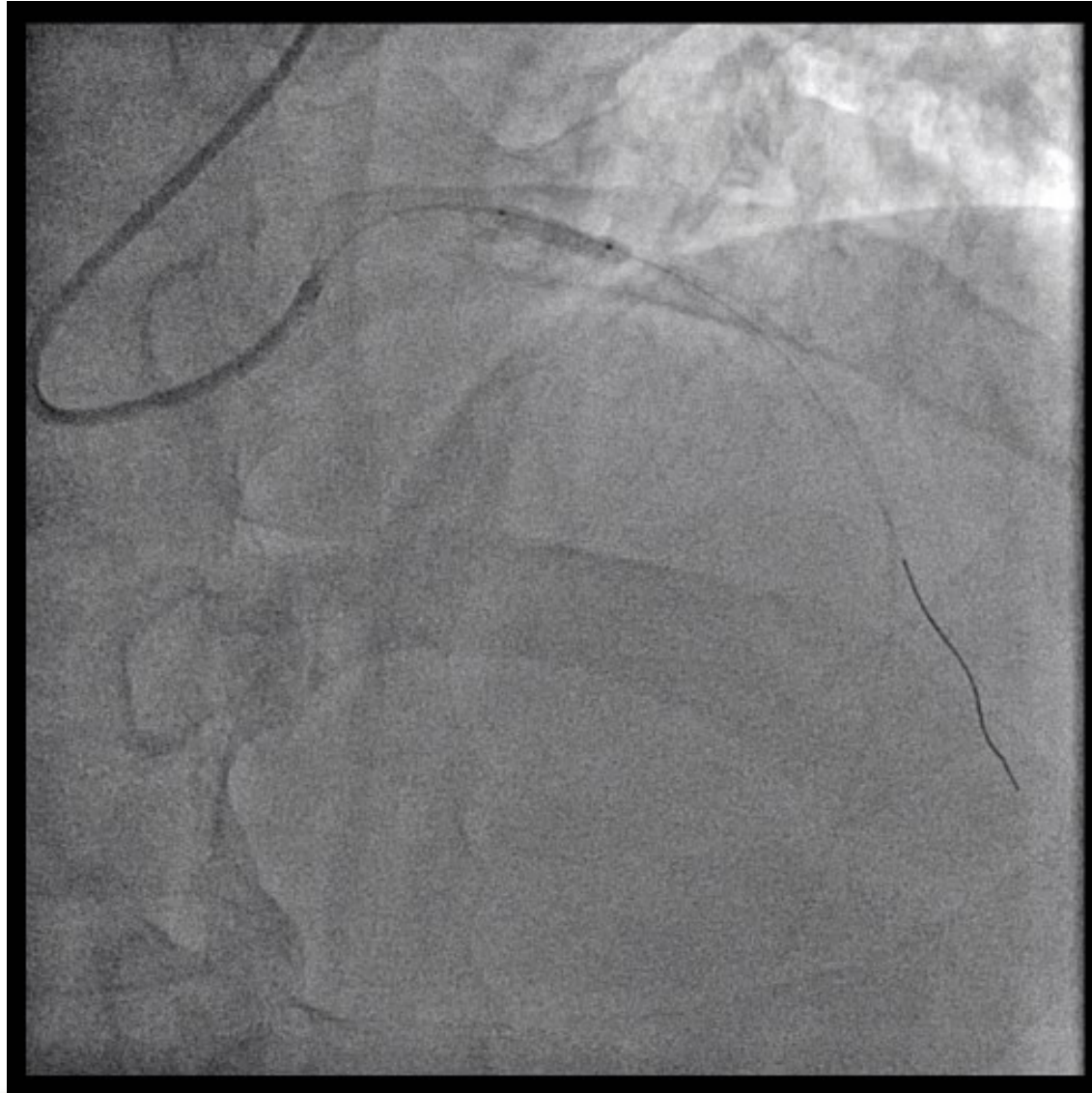


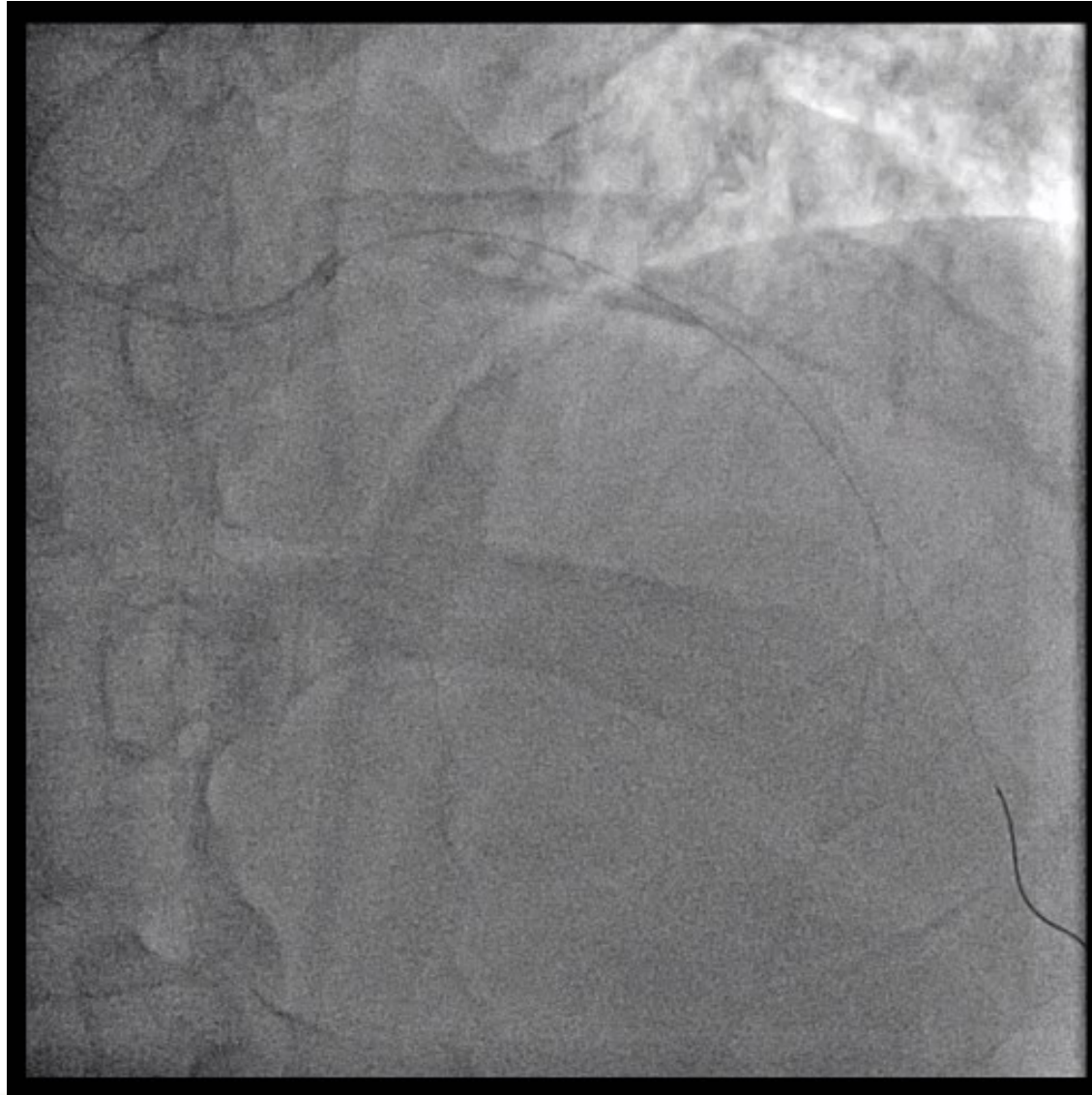
Fantom II (phase IV) registry

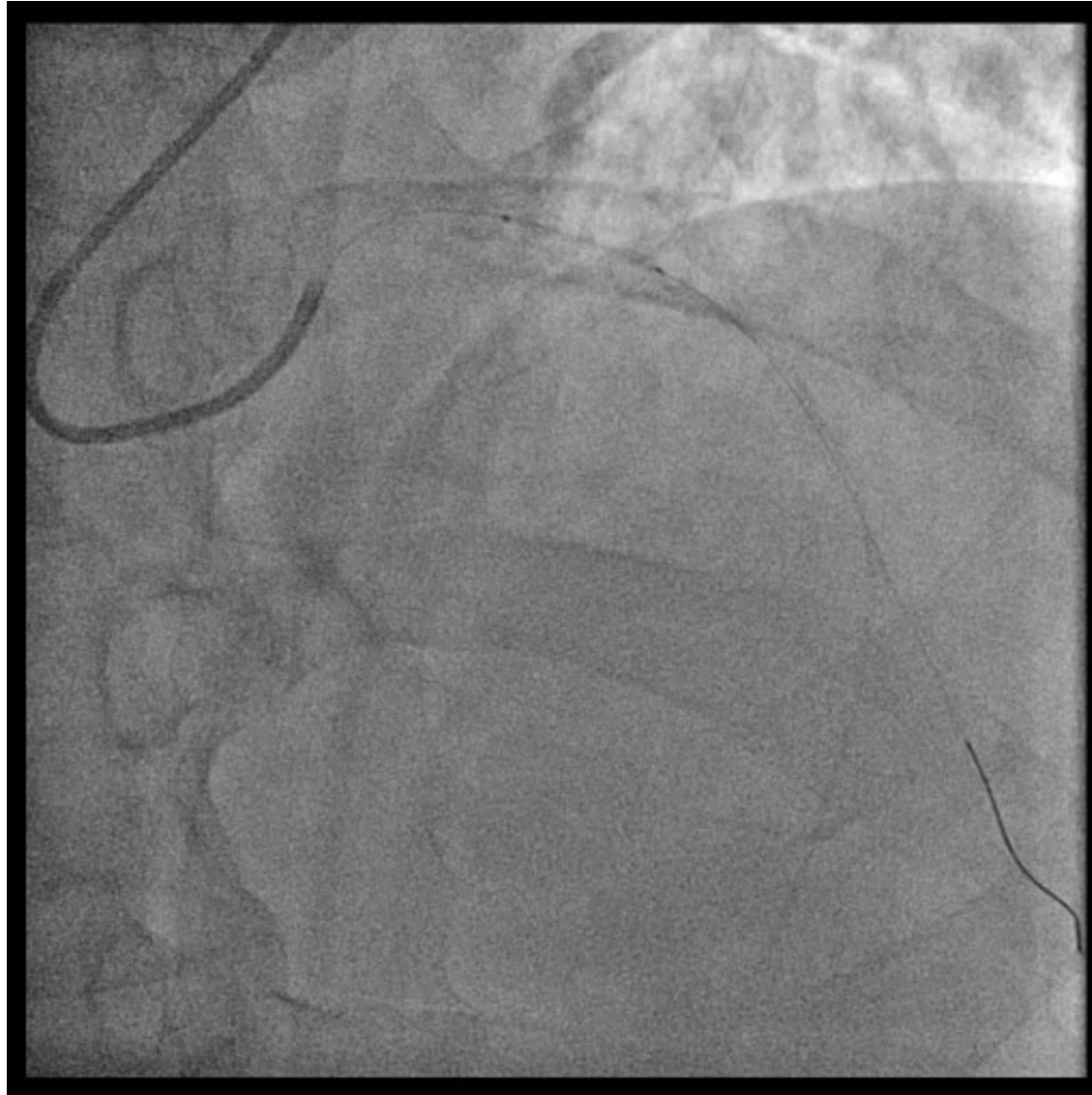
- Male
- 69 yo
- 95 kg 180 cms
- Stable angina

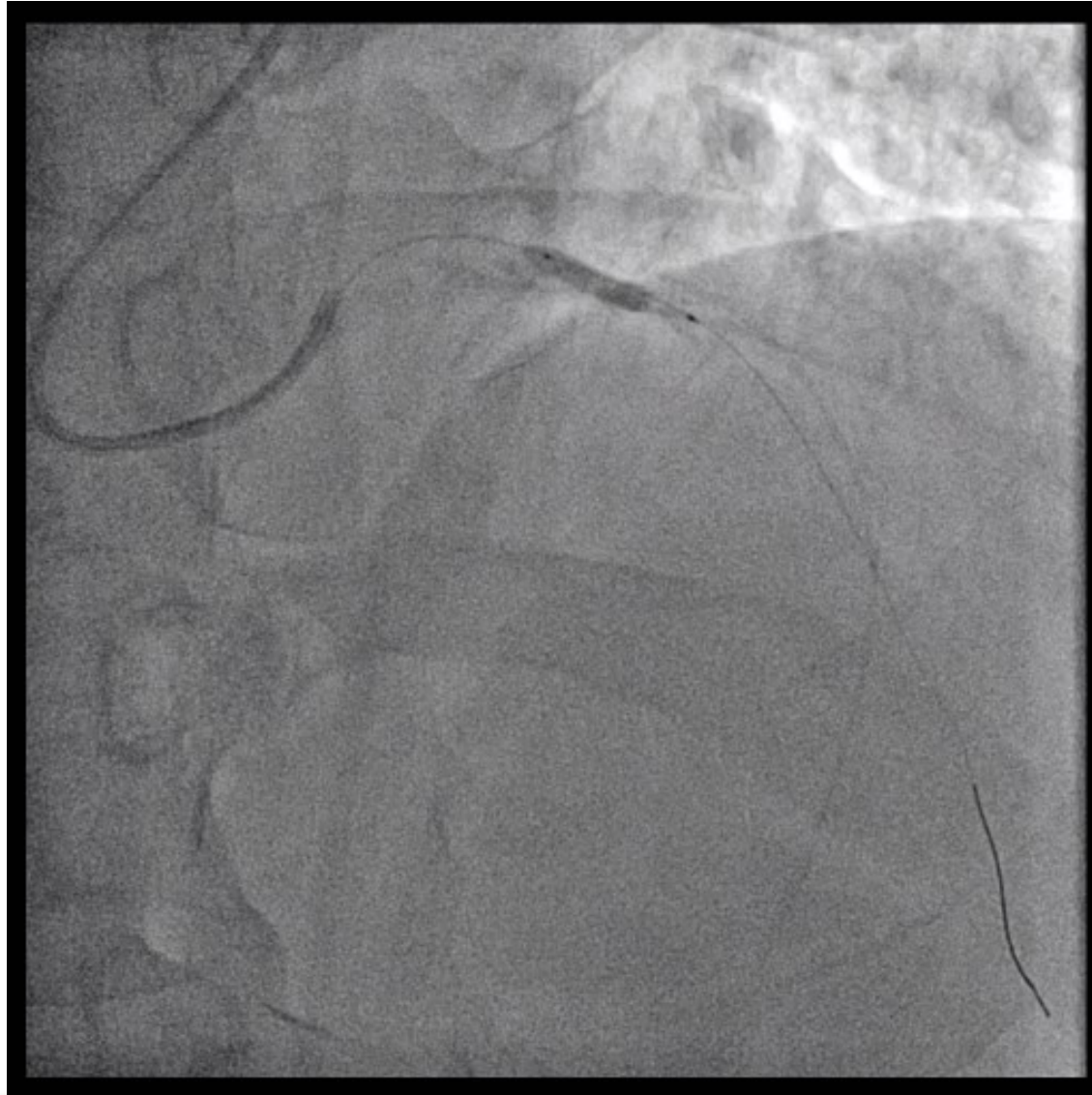

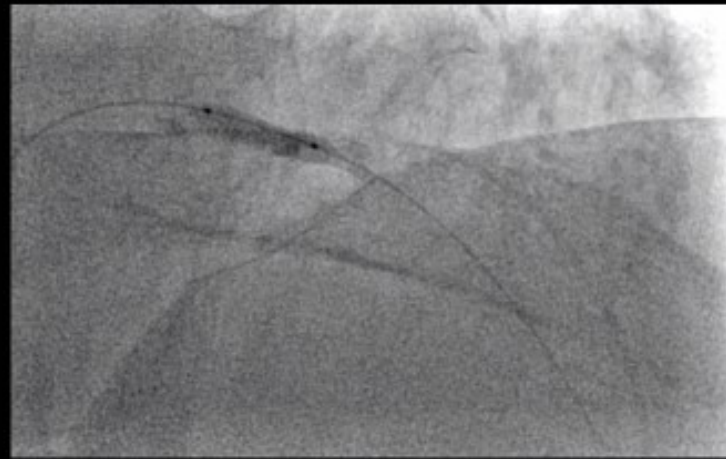



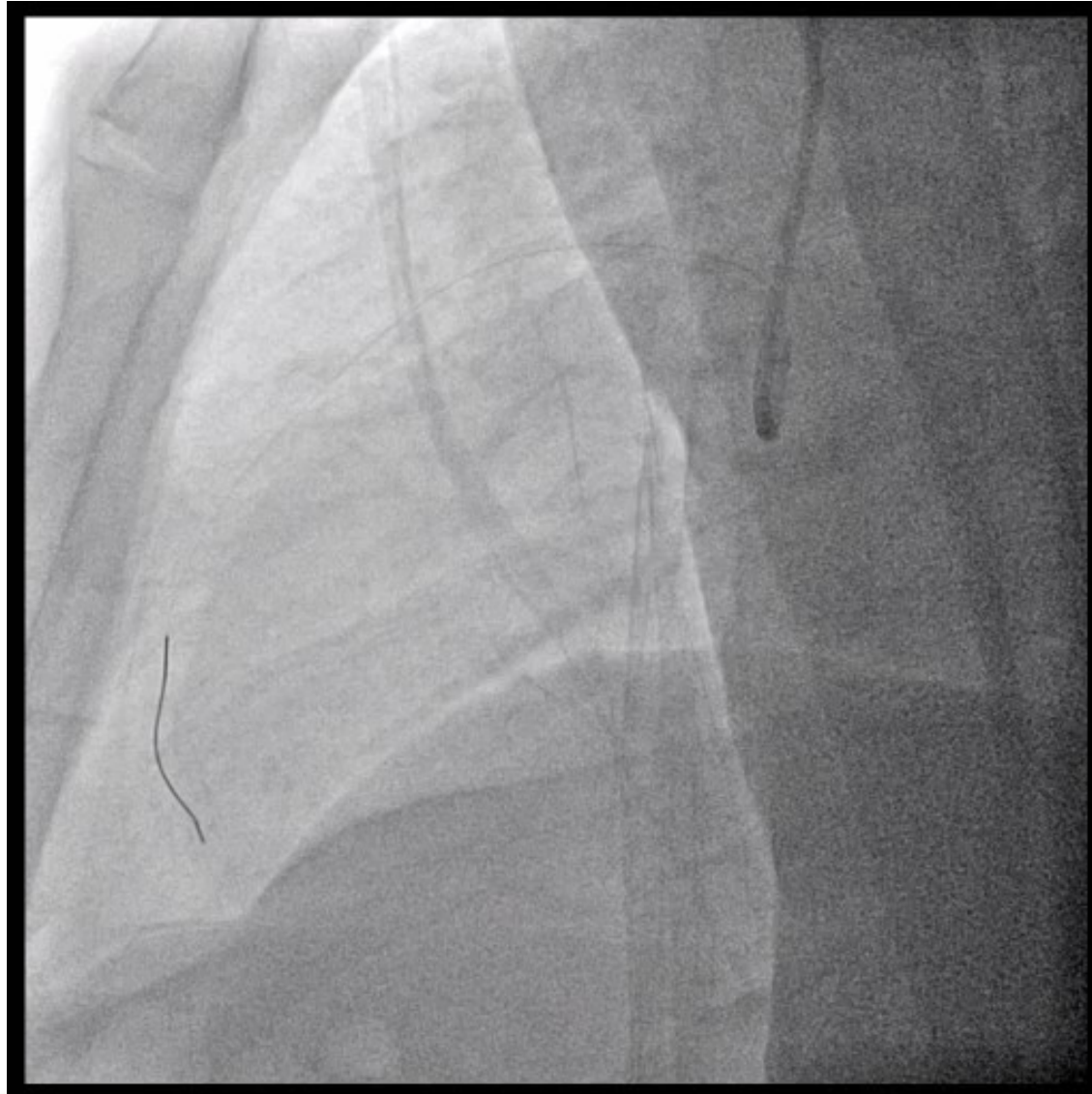


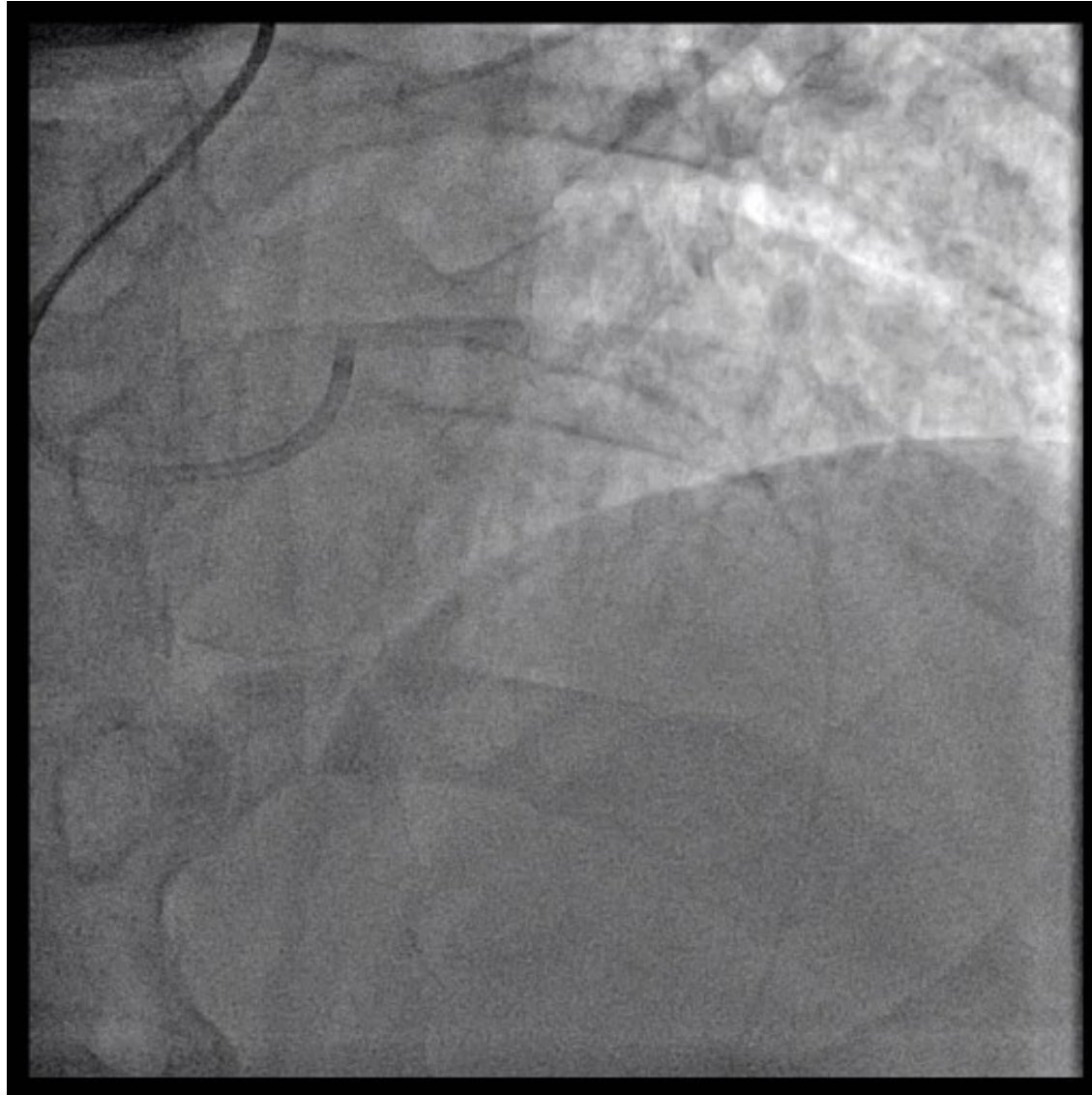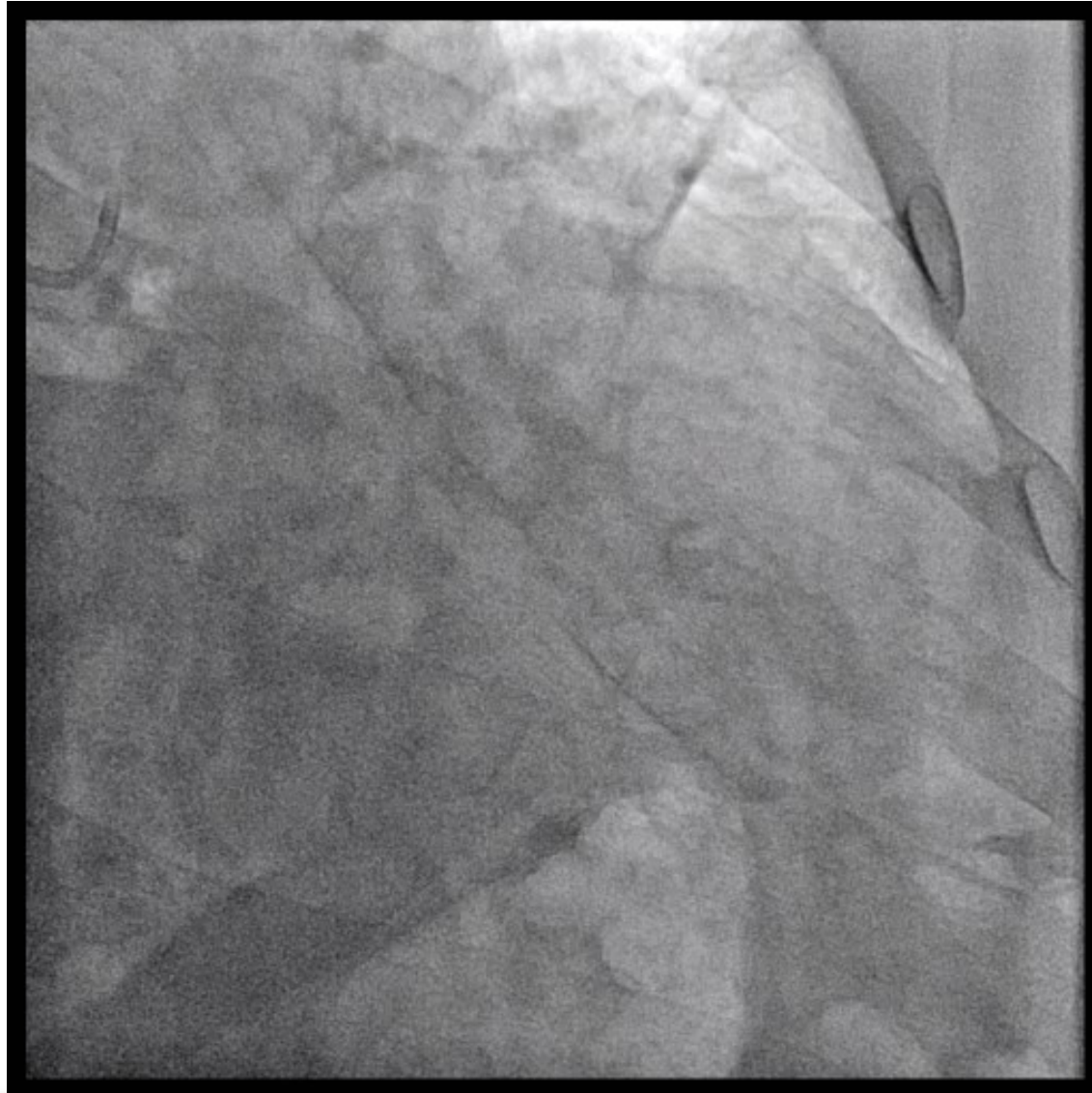


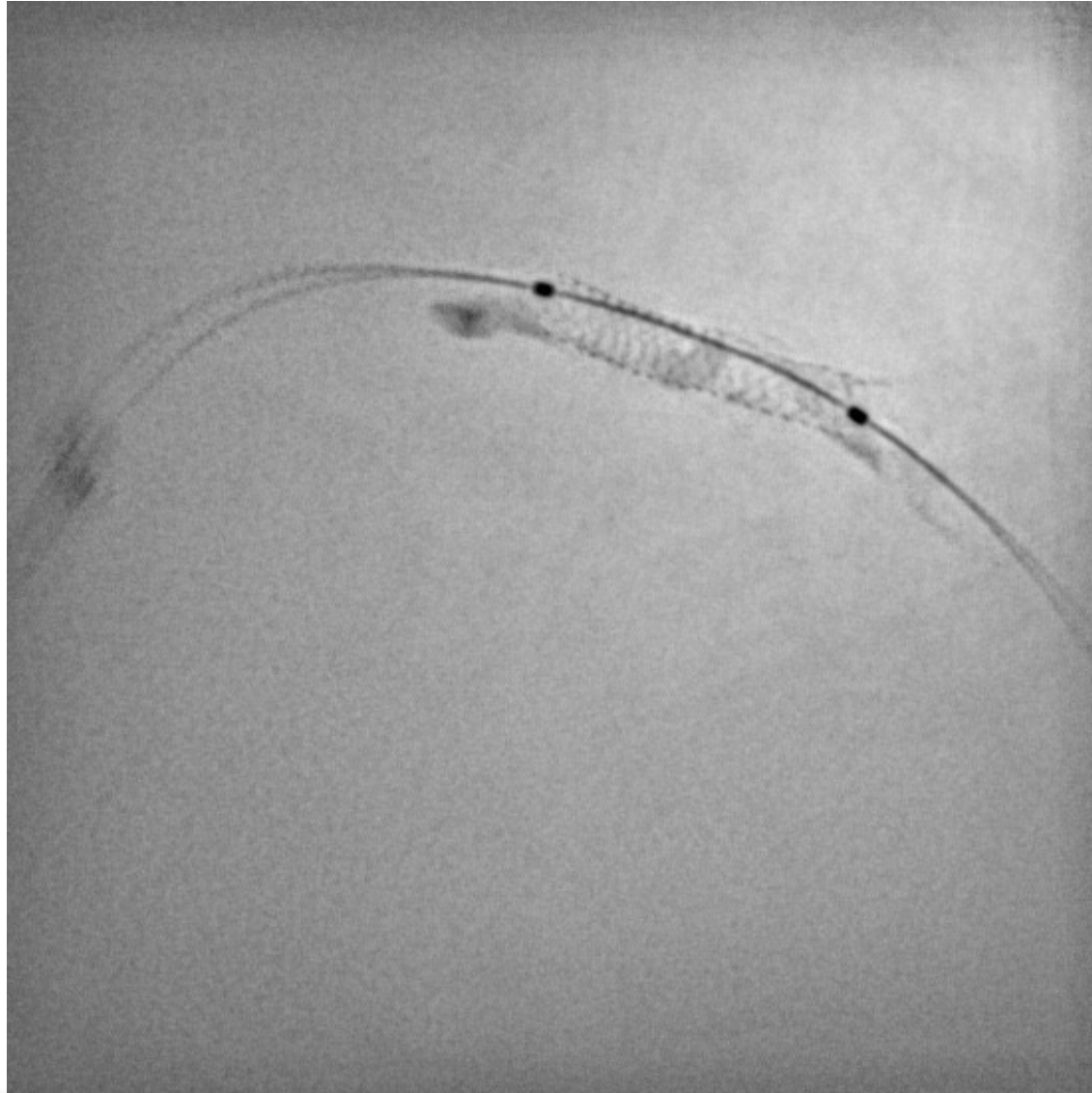


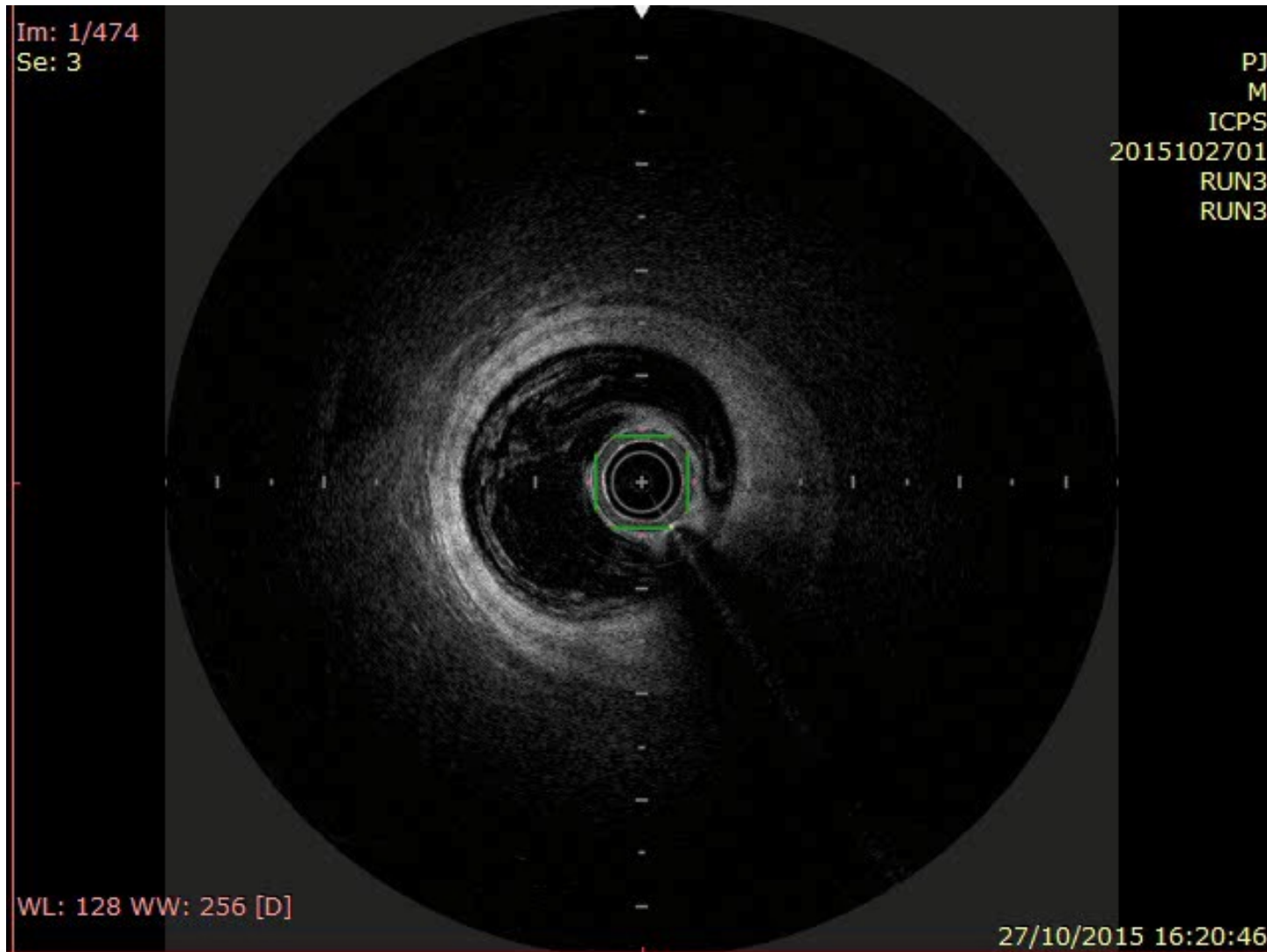




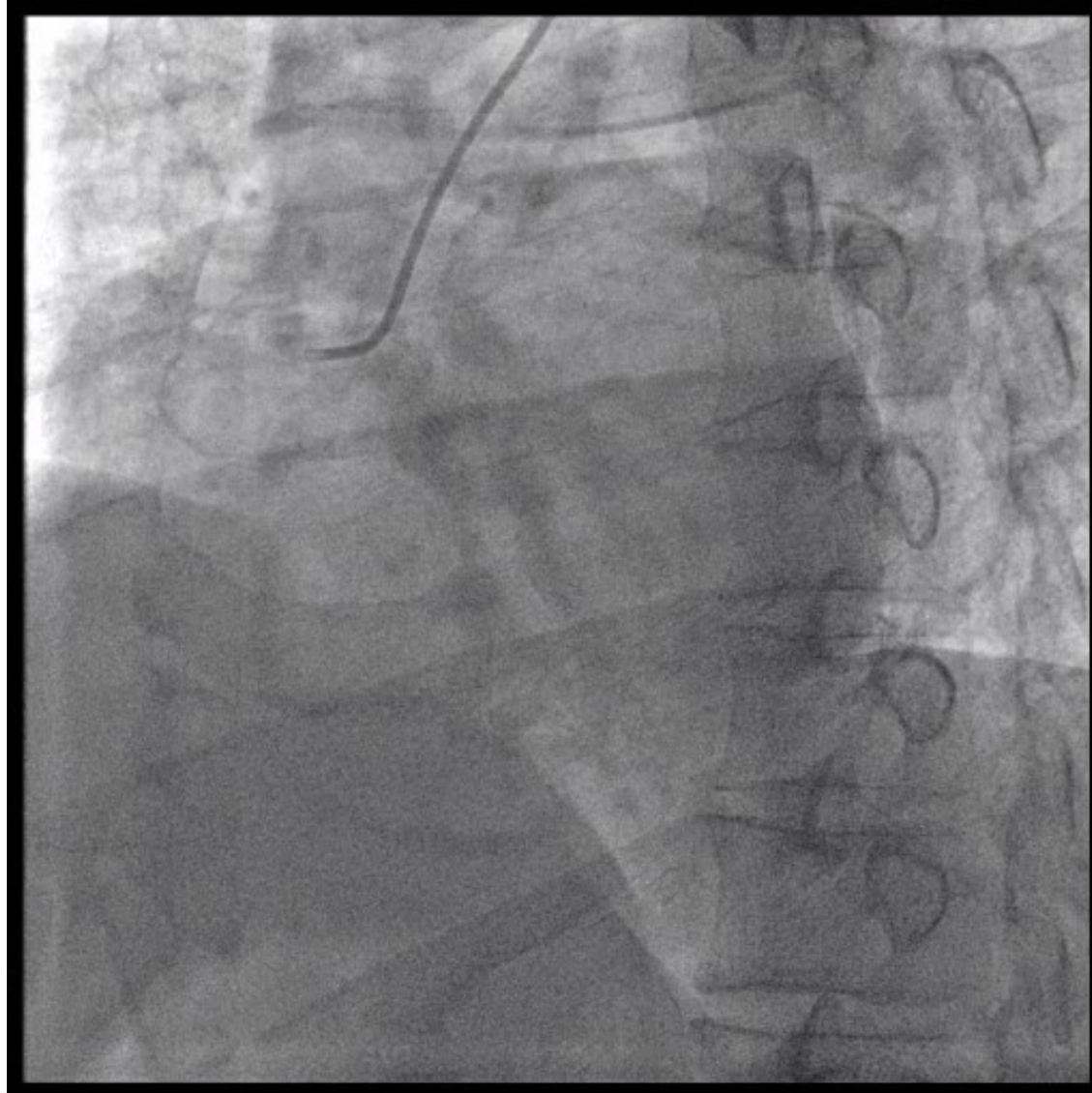


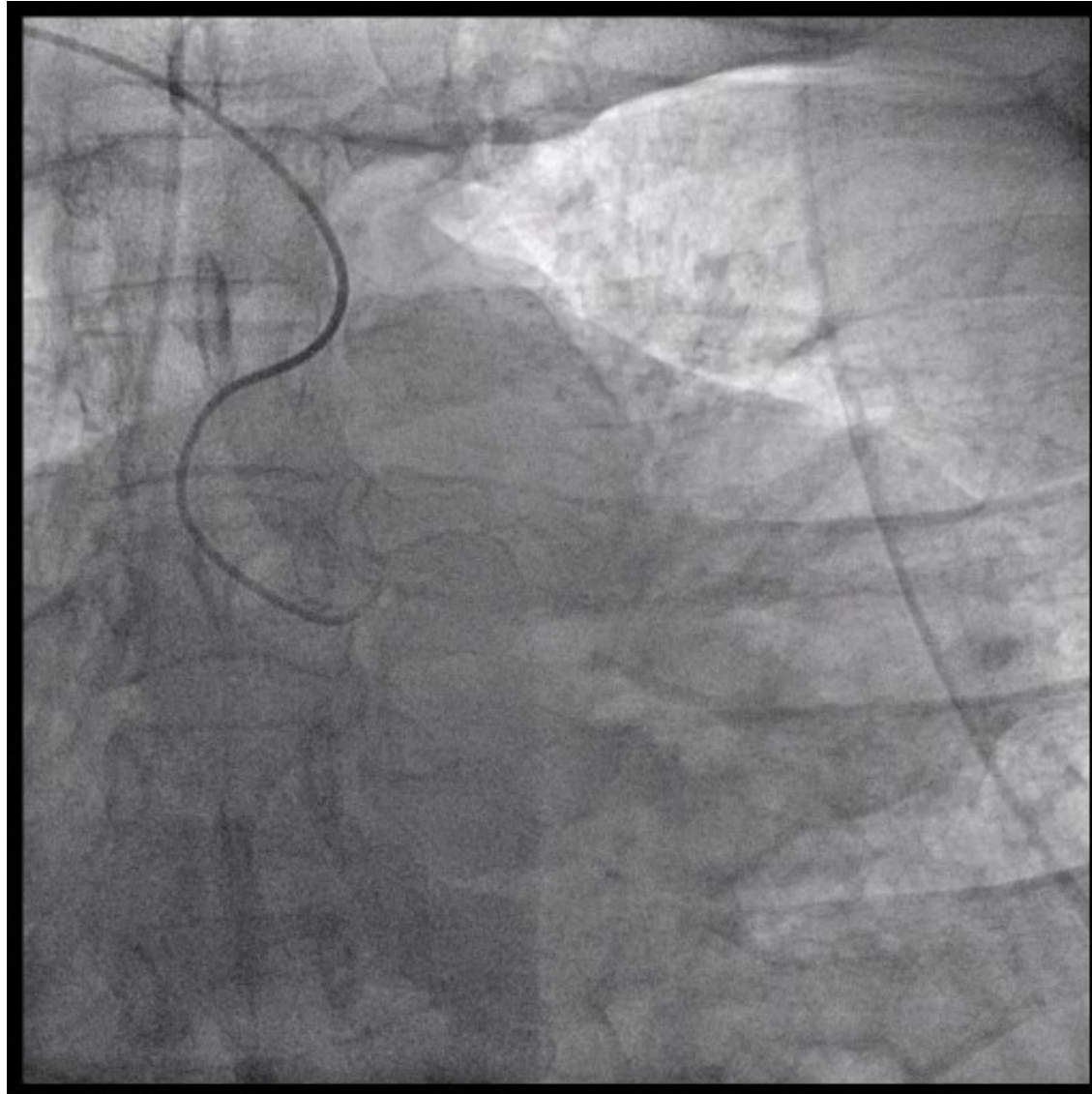


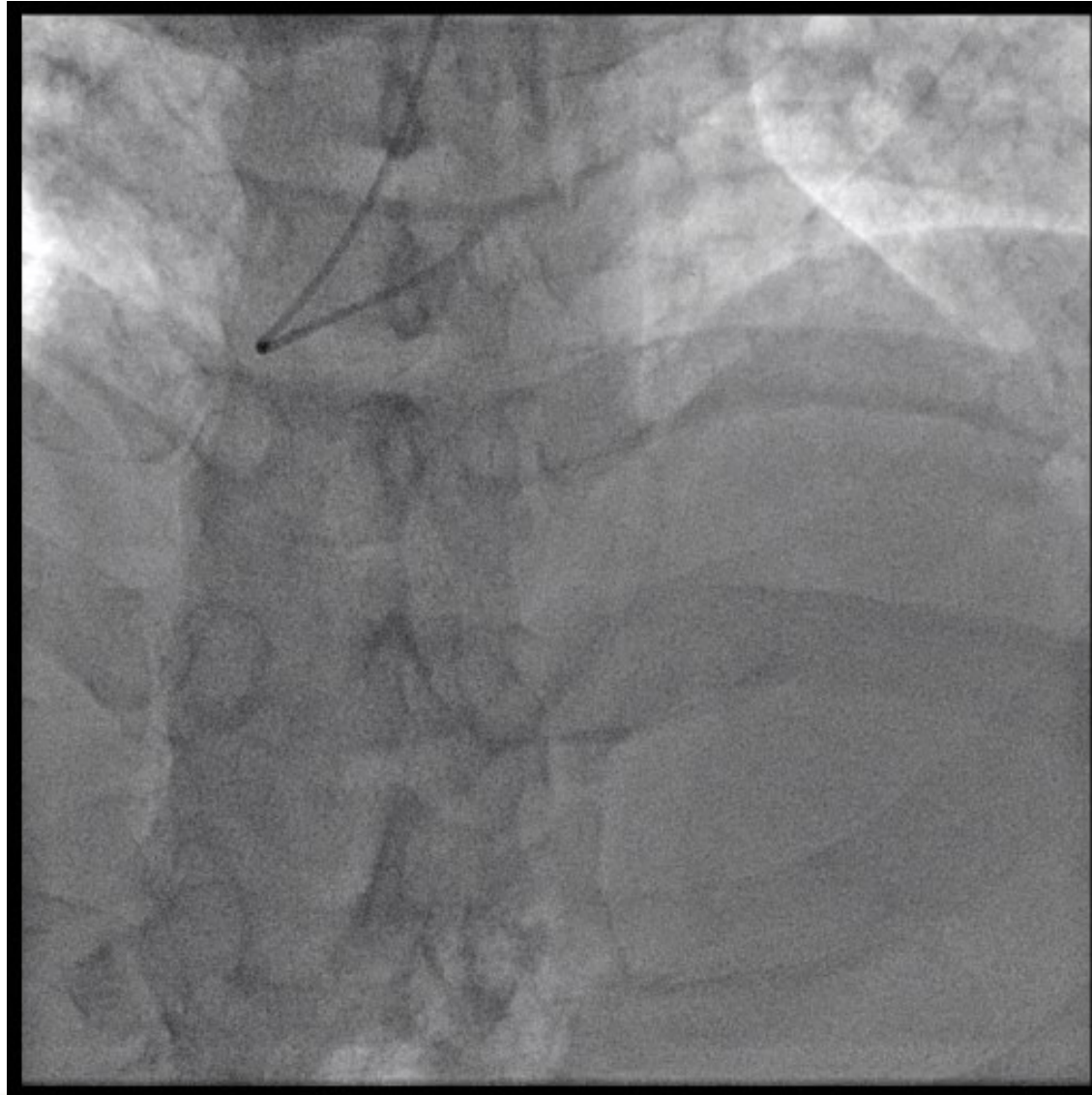


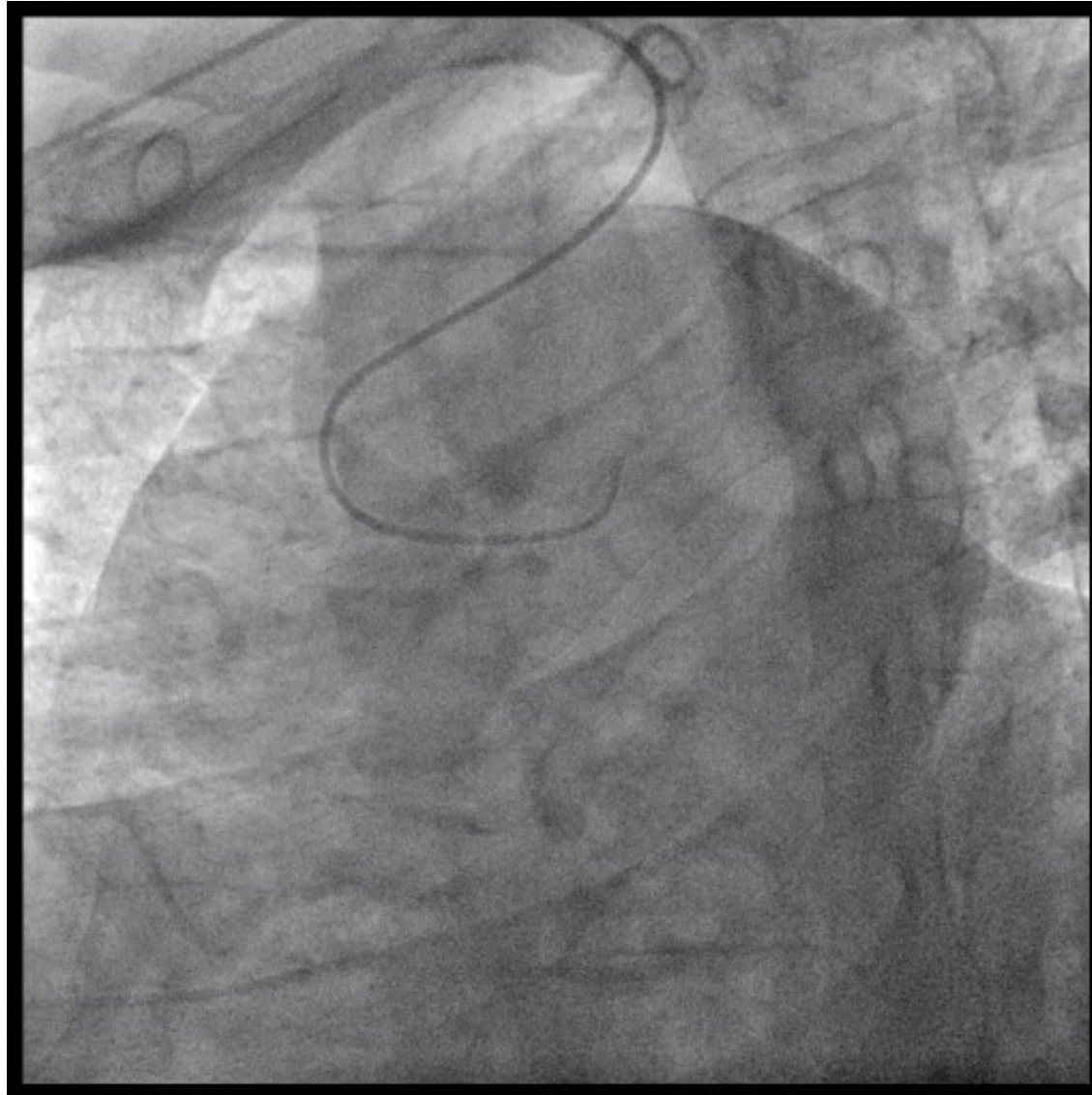


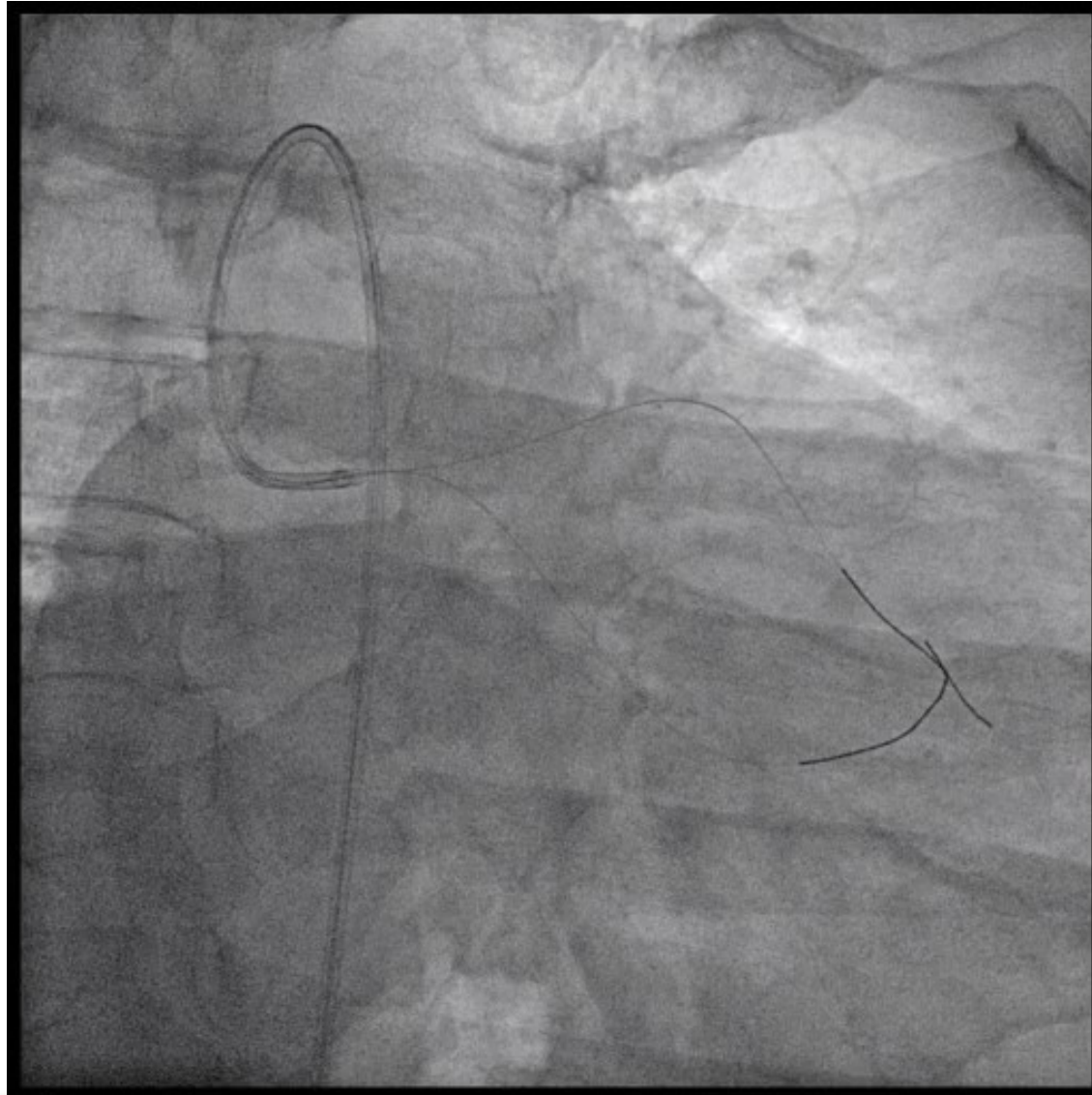
**A former ICPS fellow is not protected
against LM stenosis**

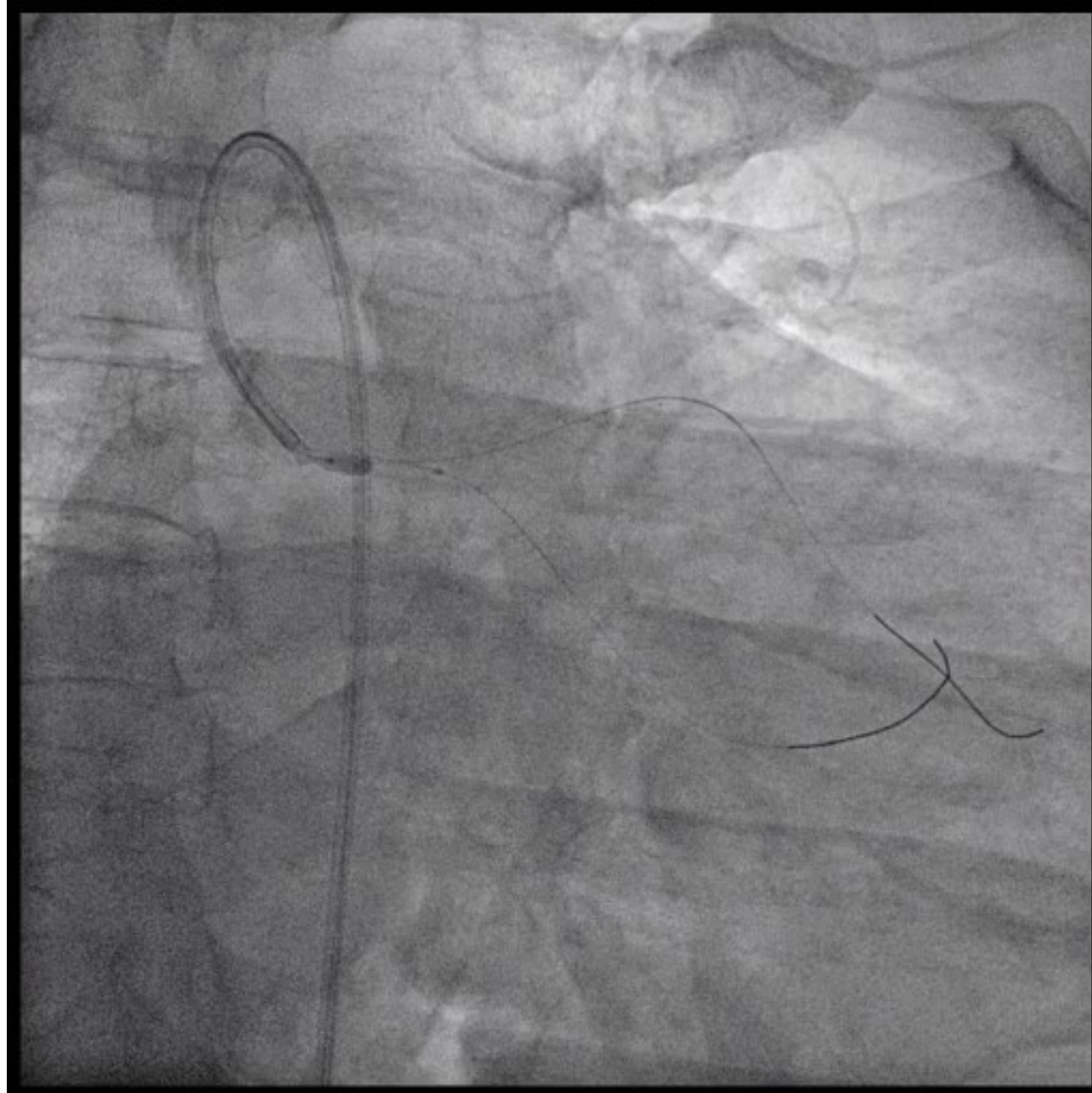


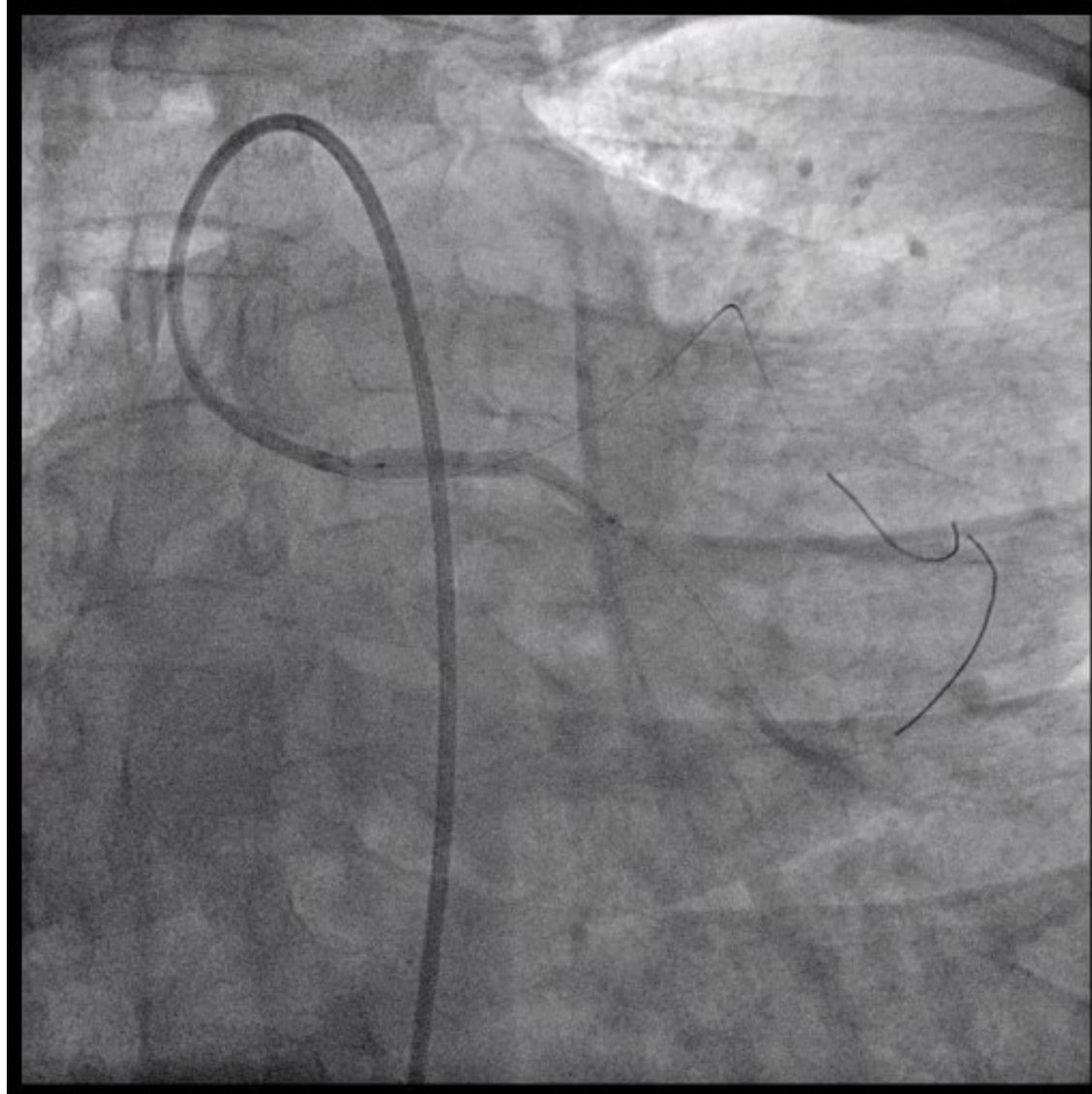


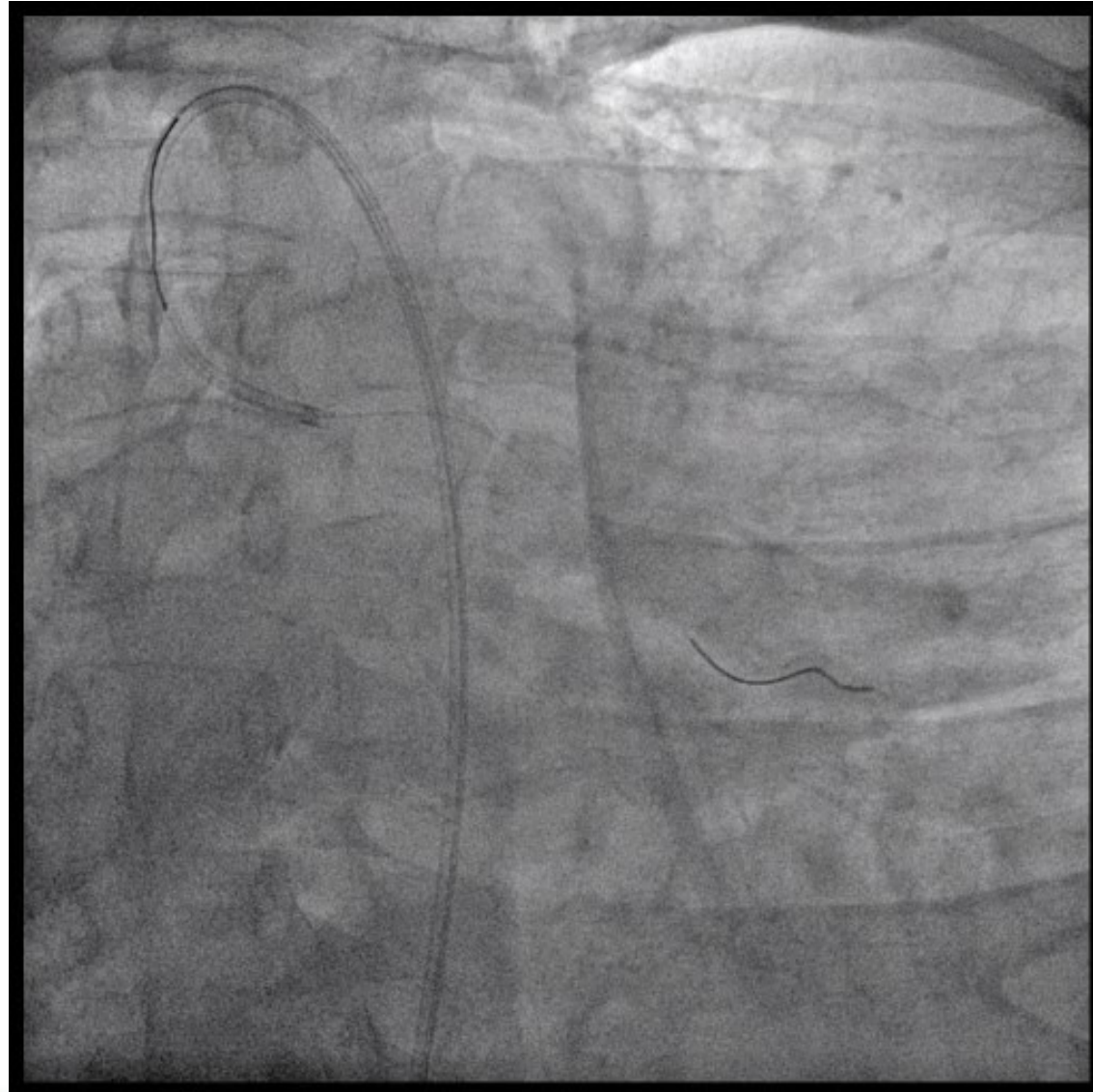

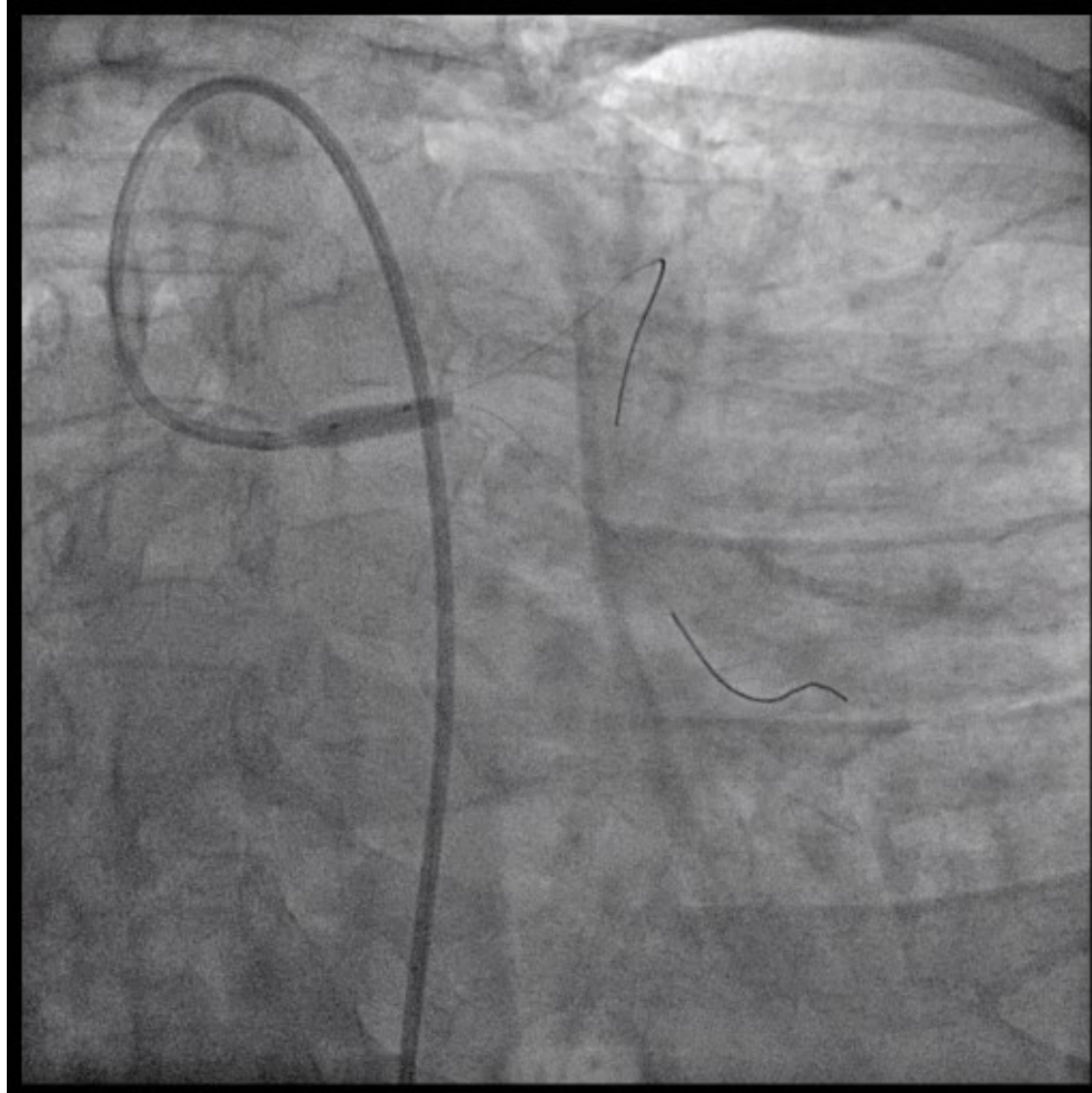


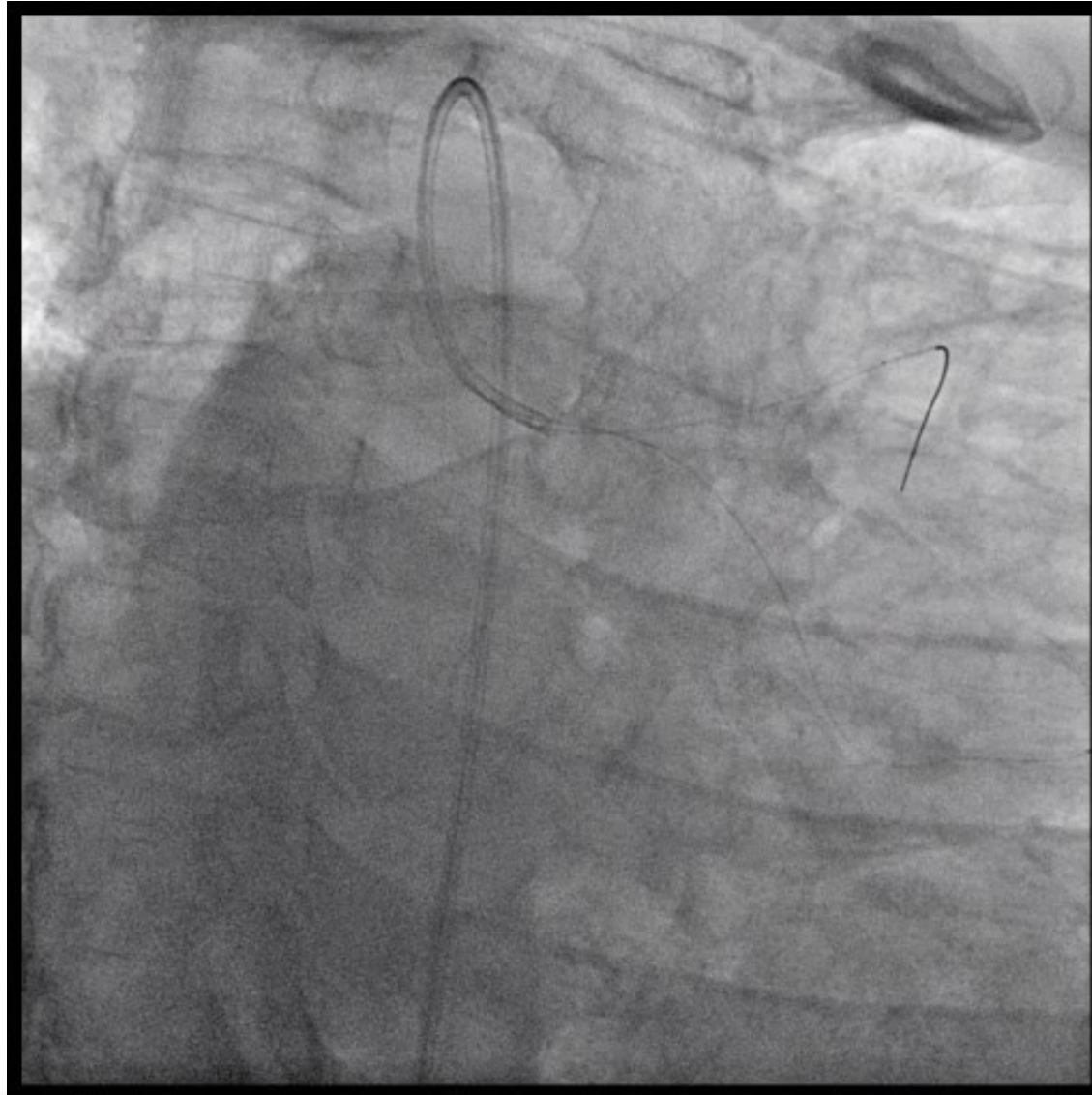



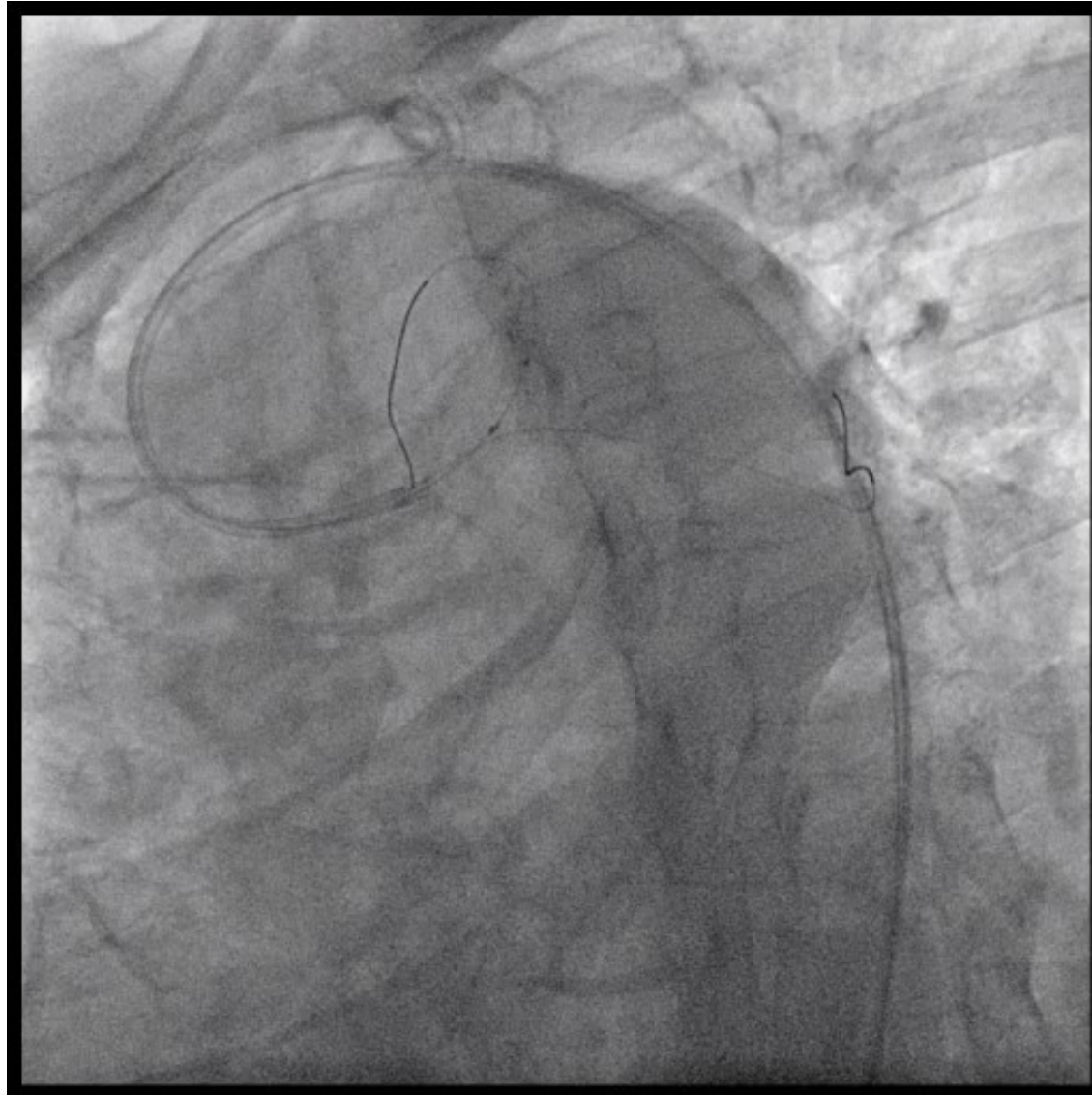


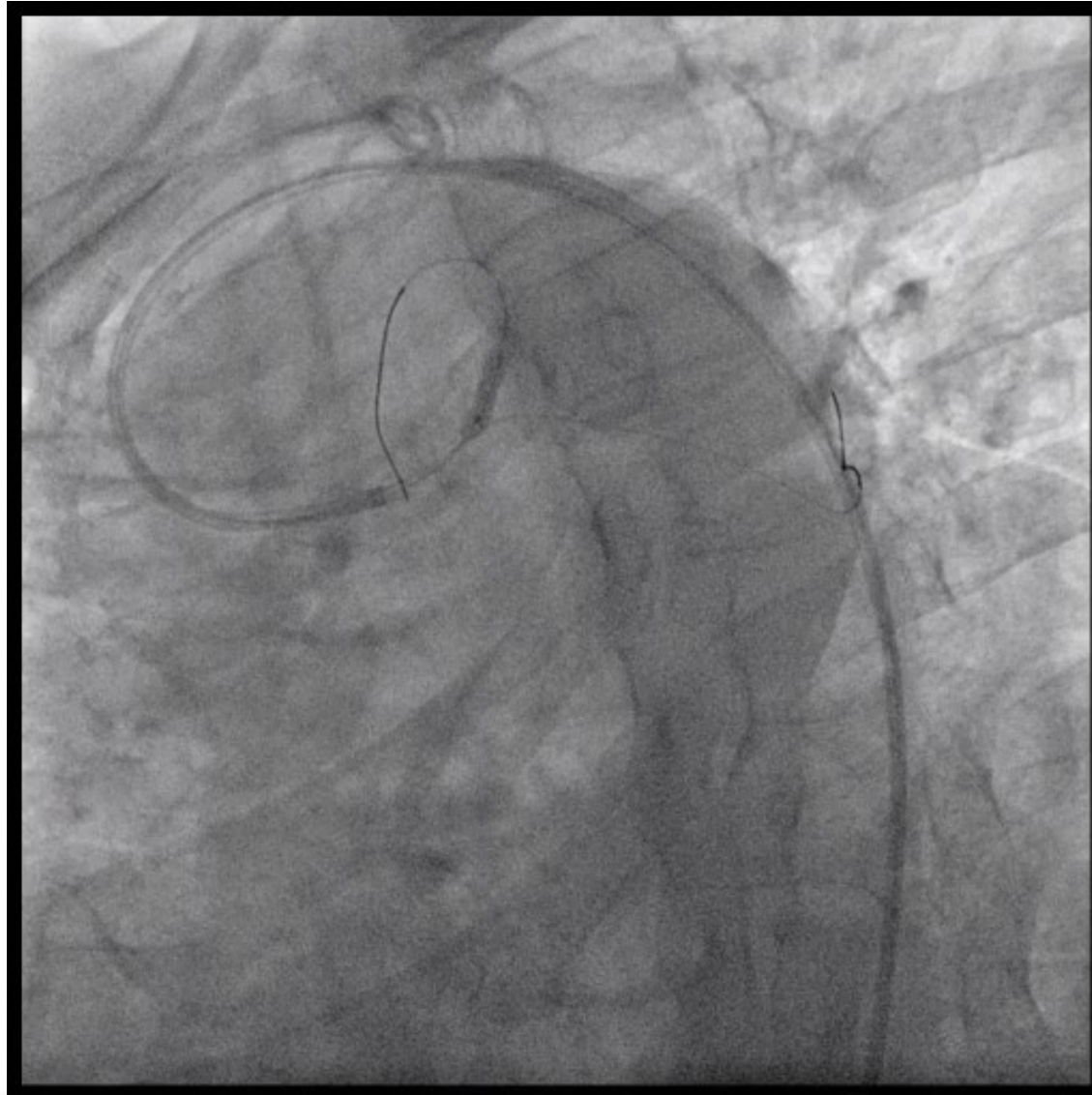





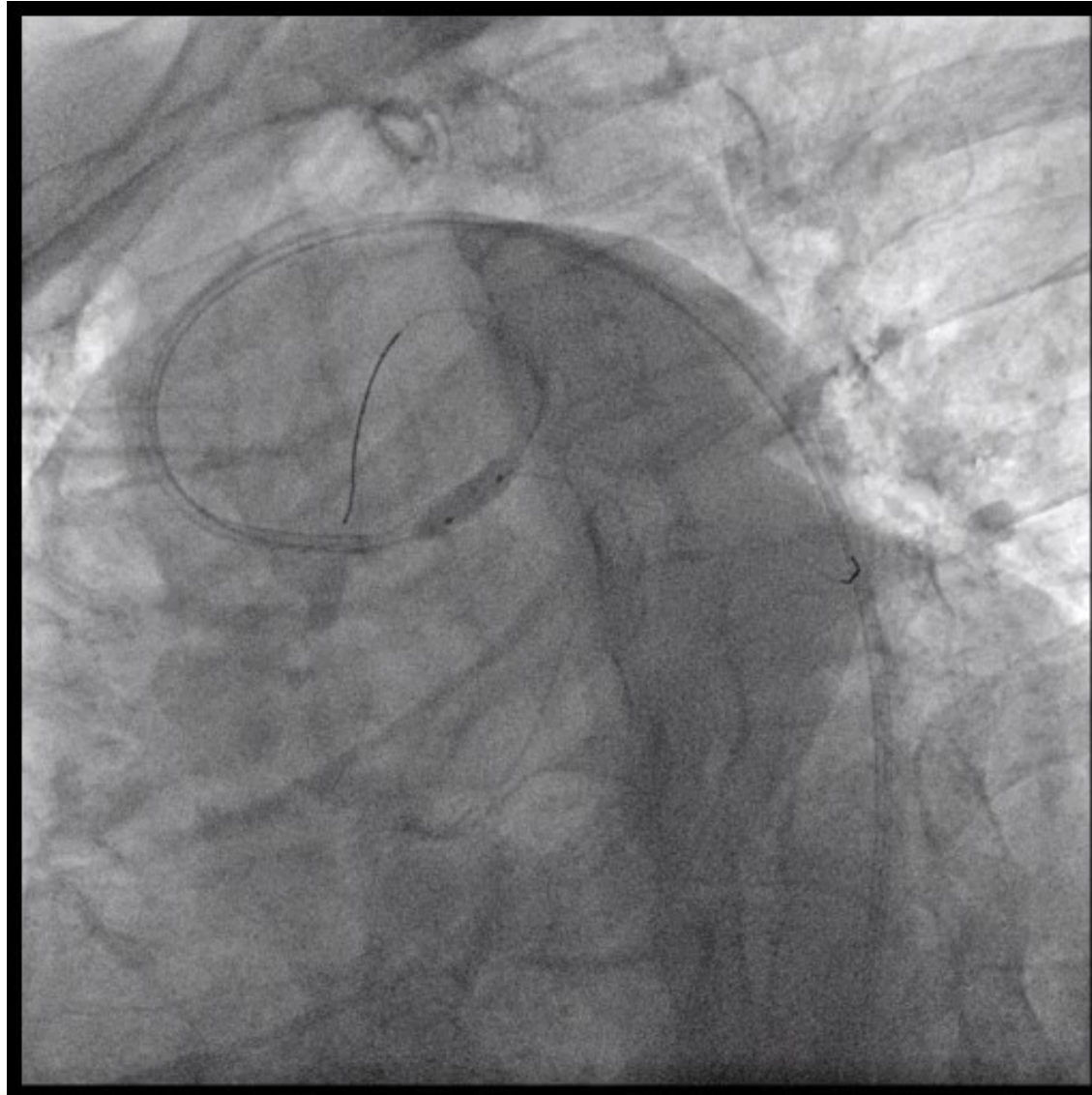


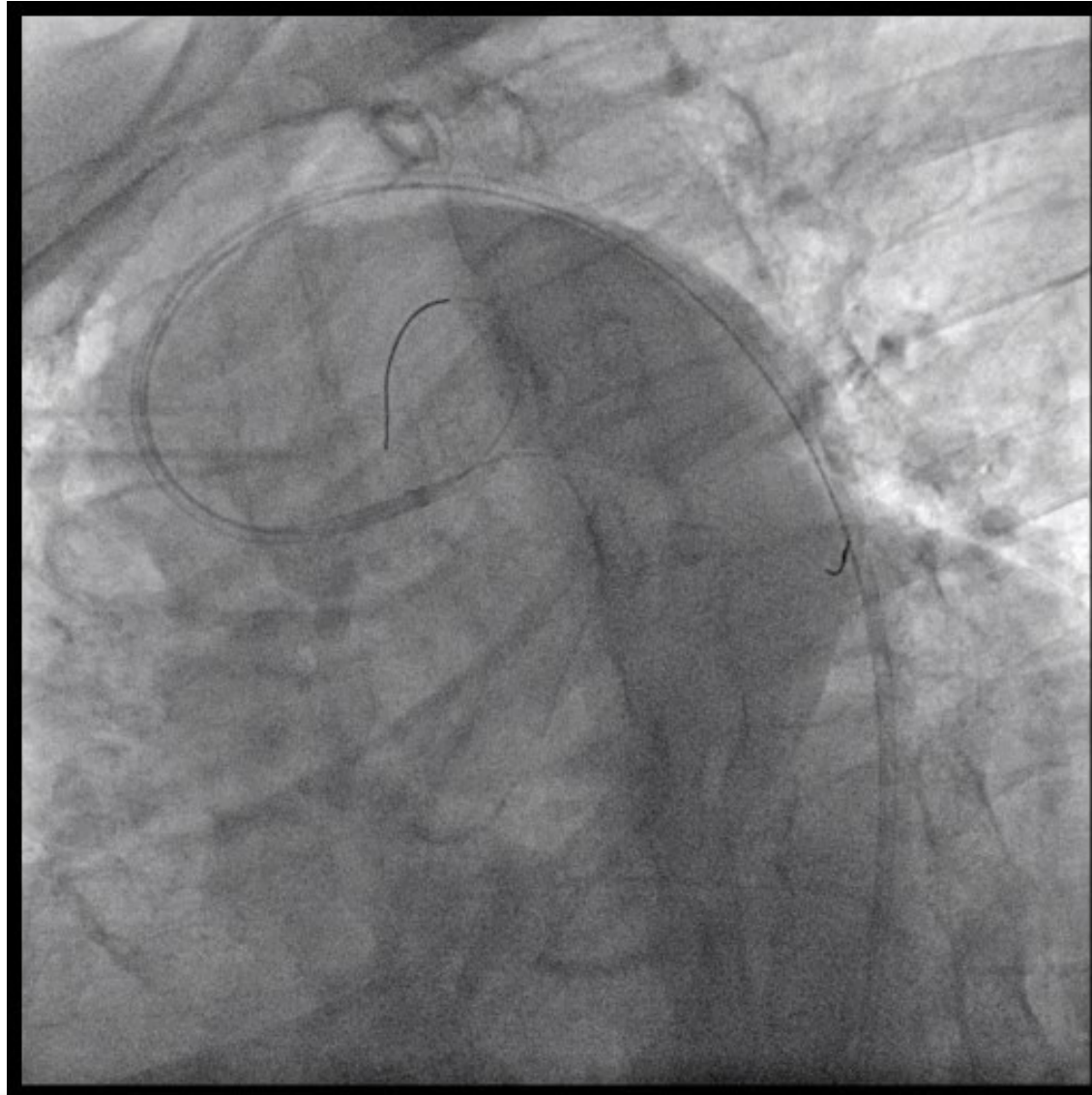






Conclusion

- Completely biodegradable
- vasomotricity restauration
- Graft anastomosis

- Difficult to implant in complex lesions: preparation
- Thickness: thrombosis ?
- Expansion: ost dilatation
- Overlapping
- Bifurcation ?
- LM ??
- CTO ???